OSCE procedures list

- low fidelity
- likely no mannequins
- for each procedure focus on VIP points not to miss and be able to troubleshoot – shows consultant level
- should be able to explain procedure to level of med student/intern
- You only have 7 minutes - read question carefully and look at domains – teaching and scholarship vs just procedure alone/medical expertise – don't waste time you don't have
- Remember exam is Australia and NZ wide exam – different equipment available in different areas (including remote posts), unlikely to be given specific kit – more likely to be asked the principles or approach to a procedure
- Some procedures are in 'the book' – MRCEM part C: 125 OSCE stations, Kiran Somani, some not
- Another nice procedure list online https://wikem.org/wiki/Category:Procedures
- Look for the addition of discriminators in the question e.g. kids/obese/pregnancy/elderly

Have a rough framework for procedure questions

PPE, consent, time out and correct patient/procedure/side

1. Indications
2. Contraindications
3. Complications
4. Equipment
5. Procedure
6. Post procedure care

Use "aseptic technique" to avoid wasting time

Consider not including an equipment list if teaching station and tell student to keep track on what is being used – saves time, avoids repetition

List of procedures expected by ACEM – curriculum framework page 76-83

https://acem.org.au/getmedia/fae9de05-e9c2-40d3-bee9-be1e66b3b84f/ACF440_0-5.aspx

The following list has been extrapolated from this to try and identify the most likely procedures that could come up in the fellowship OSCE. It is not exhaustive

*all procedures related to practice and procedures pre-covid

CONTENTS

Burns

Micro

ENT

Opthal

USS

Toxicology

Extra

Normal airway, simple manoeuvres & adjuncts

- Be able to describe and teach/perform

- Escalation of supplemental oxygen up to 15L NRB
- Use of BVM/Mapleson circuit – 1 & 2 handed
- Jaw thrust/head tilt and position in kids & adults
- Initiation of HFNP02 humidified
- Application of NIV
- Intubation
- LMA insertion – pick your fav LMA and know how to use it (supreme/classic/igel)
- Difficult airway algorithm
    - Surg cric >12 y/o
    - Needle cric <12 y/o

- Adjuncts

- NP – size patients pinkie finger
- Guedel – front teeth to angle of jaw
    - >8 y/o insert upside down like adults
    - <8 y/o tongue depressor and concave

Difficult airway algorithm & surgical airway

- Basics most VIP
- Optimise patient – preoxygenation & position e.g. ramped in obesity etc
- Ear same level as sternal notch
- Have logical escalation – DAS vs vortex – pick your fav and know it
- If scenario becomes a CICV or situation of potentially difficult airway decide already if you personally would do a needle cric vs surgical cric (nb needle cric can ventilate but not oxygenate)
- Be very clear re timing of moving to front of neck access

✓ Indications
- CICV
- Predicted difficult airway – oedema, burns, bleeding – remember 2 teams, local to site already, try top end first

✓ Contraindications
- Unlikely if you've already committed to an airway
- Unsurviveable injuries
- Lack of equipment/skillset
- NFR

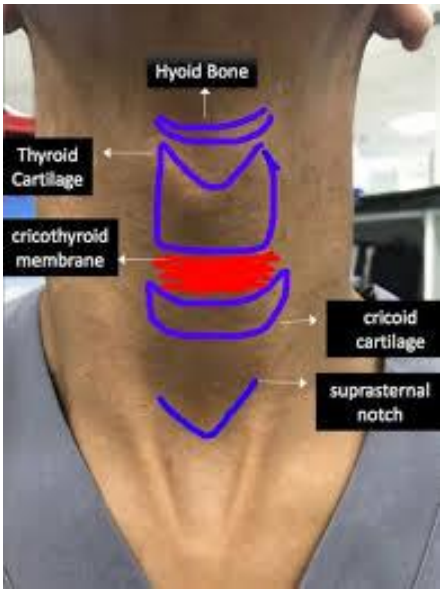

✓ Complications
- Failure
- Bleeding
- Infection
- Loss of airway
- Damage to adjacent organs

✓ Procedure (obese surgical described)
- Anatomy VIP – cricothyroid membrane as pic
- Approach can depend on patient's anatomy
  - slim and obv landmarks – scalpel, bougie, ETT
  - obese/diff landmarks – larger incision vertically, finger, scalpel, bougie, ETT
- PPE, aseptic technique, local anaesthetic if time
- Vertical incision – potentially large one – will bleed
- Finger to membrane
- Horizontal through membrane with scalpel
- ¼ turn, bougie and size 5 ETT

✓ Post procedure care
- Confirm placement – look, listen, feel, c02
- Secure ETT
- ENT for definitive airway

Currently in ED plan A likely to be with video laryngoscopy

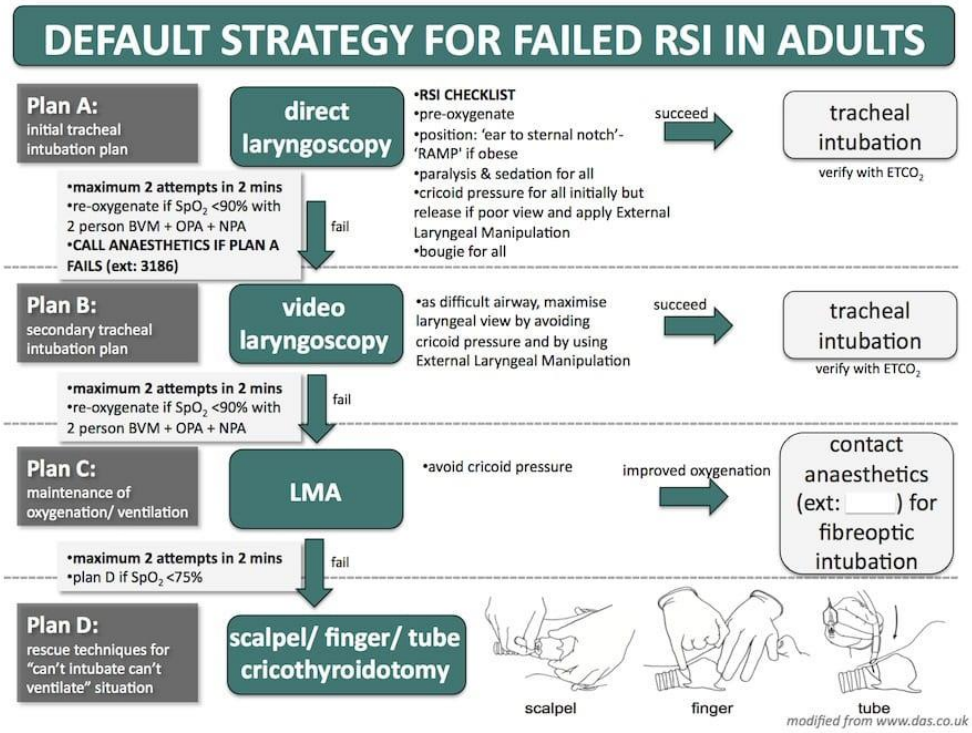

Or DAS and vortex – pick your fav and use that

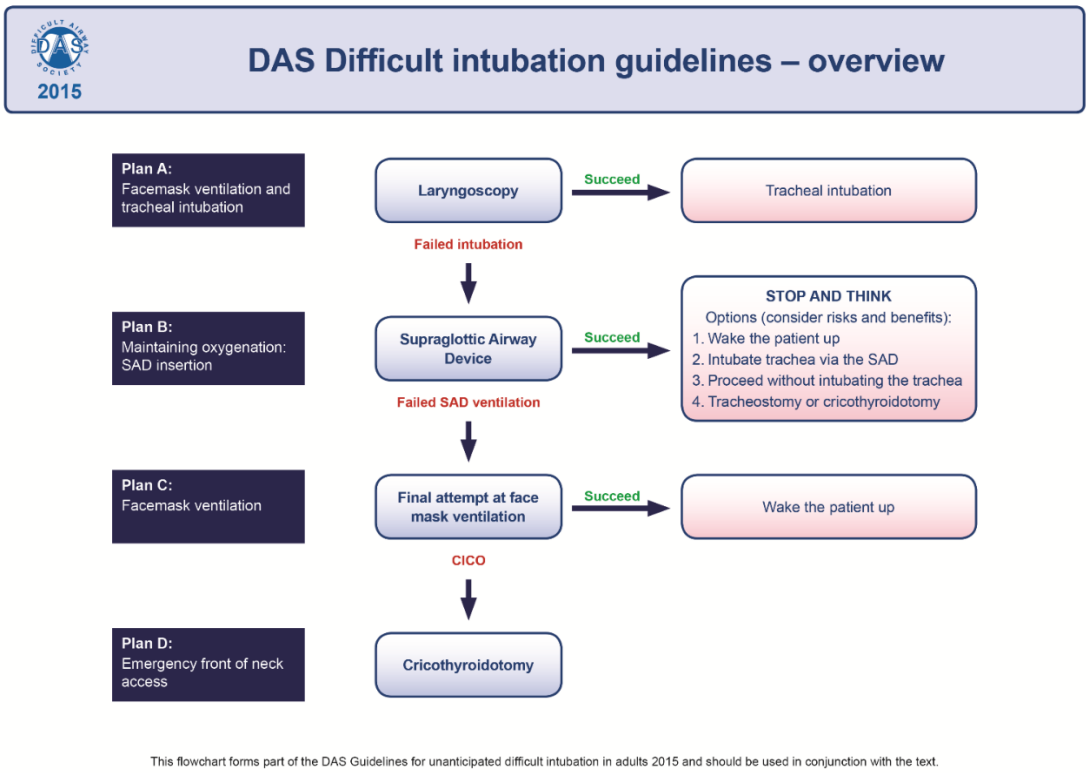

THE VORTEX

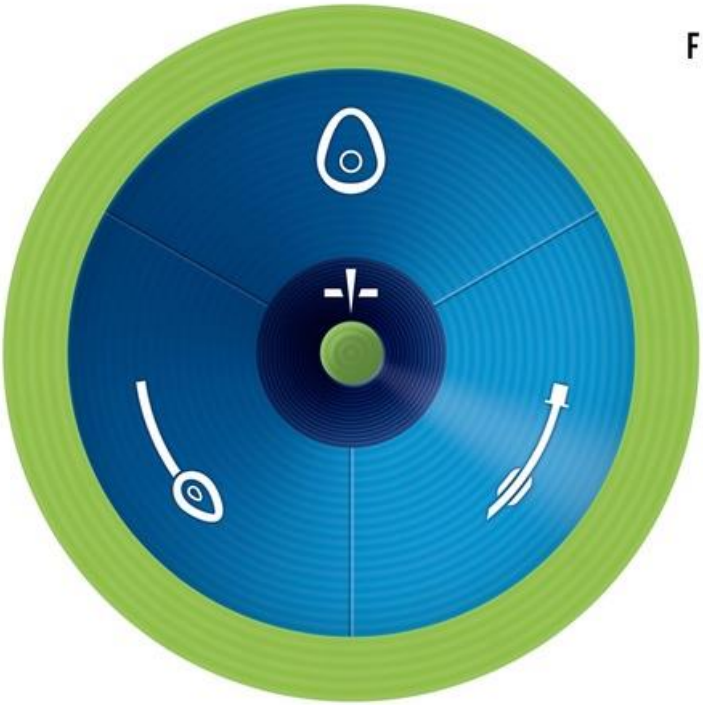

FOR EACH LIFELINE CONSIDER:

MANIPULATIONS:
- HEAD & NECK
- LARYNX
- DEVICE

ADJUNCTS

SIZE / TYPE

SUCTION / O_2 FLOW

MUSCLE TONE

MAXIMUM THREE ATTEMPTS AT EACH LIFELINE (UNLESS GAMECHANGER)
AT LEAST ONE ATTEMPT SHOULD BE BY MOST EXPERIENCED CLINICIAN
CICO STATUS ESCALATES WITH UNSUCCESSFUL BEST EFFORT AT ANY LIFELINE

VortexApproach.org

Peak flow/inhaler technique

- Peak flow
  - Chart for age and height
  - Normal for patient
  - If low can be indication exacerbation disease but not as good as hx/examination
  - Patient must be standing up
  - Blow out as hard and fast as possible
  - Best of 3 (noting if unwell 3rd likely to be worst, however may account for poor technique)

- Spacers
  - When used properly as good as nebulisers
  - Ensure med to lungs
  - Allow for poor co-ordination
  - Facemask vs good seal lips

✓ Indications
  - To deliver any MDI medications – adult or child

✓ Contraindications
  - None really
  - Use mask attachment for those too young to co-ordinate with mouthpiece

✓ Procedure
  - Wash spacer every month or if unwell
  - Soapy warm water
  - Don't actively dry with tea towel etc
  - Drip dry only (reduces static)
  - Shake MDI canister for 5 seconds
  - Prime new/clean spacer with 10 puffs
  - Then 1 puff through spacer for every 3-4 breaths of patient
  - Shake and repeat

✓ Post procedural care
  - If possible, show parents how to do it on child and allow them to try to assess for correct technique
  - At discharge patient needs written and verbal discharge advice
  - When to return
  - GP follow up
  - Asthma/wheeze action plan

NIV

- NIV = BIPAP, CPAP just gives EPAP – increased peep but doesn't ventilate patient
- BIPAP – COPD/asthma – increased peep, increased pressure support, increases patients o2 and decreased co2
- CPAP – cardiac/APO – increases PEEP and therefore increases patient o2 and decreased WOB
- To increase o2 – increase EPAP (increases peep and recruitment)
- To decrease co2 – increase IPAP (increases tidal vol and 'blow off co2')

✓ Indications – start with hx, ex, ix (cxr/abg)
- COPD with resp acidosis
- Type 2 resp failure secondary to chest wall deformity and neuromuscular disease
- Cardiogenic APO – unresponsive to CPAP
- Pre oxygenation for induction

✓ Contraindications (think of anatomically from top of head down)
- VIP decide ceiling of care
- Low GCS
- Facial injury/surgery/oedema
- Fixed airway obstruction
- Pneumothorax
- GI surg/obstruction/vomiting
- Non co-operation
- Needs ETT

✓ Complications
- Failure
- Hypotension
- Poor tolerance
- Pneumothorax
- Aspiration
- Facial injury from mask

✓ Procedure
- Consent patient – likely verbal
- Sitting up – NIV machine, circuit, nebs/inhaler ports/filters as required
- Mask fitted correct size (cut outs in packs)
- Reassurance and holding mask close
- BIPAP – EPAP 4 and IPAP 10 (min 4 in-between)
- 100% Fio2 and titrate
- Once comfortable titrate pressures

✓ Post procedure care
- Hourly ABG and review
- If deterioration – ETT vs ceiling of care

T piece resuscitator

- Neopuff – can supply blowby o2 (occlude peep valve), CPAP and PPV
- Used in preference to BVM/bag with flow as T piece can be controlled
- PEEP and PIP – constant settings, can control length insp and exp
- Improves lung expansion/oxygenation

✓ Indications
- Neonatal resus
- HR <100 – PPV
- Hr >100 and laboured breathing CPAP

✓ Contraindications
- Possible congenital facial abnormalities or injury – may need ETT
- Airway obstruction – suction +/- ETT

✓ Complications
- Overdistention
- Pneumothorax
- Lung injury

✓ Equipment
- Neopuff and mask/supply line
- Neopuff machine
- Gas supply line
- +/- test lung

✓ Procedure/set up
- Turn on air and o2 – set at 21% on mixer with 10l flow
- Check max pressure relief valve (covered under cap) – max 40cmh20
- Set peep by holding to hand – 5cm h20
- Then occlude cap and set PIP – 30cm h20 in term baby
- 40-60 breath per min until HR >100bpm. Working if patient is improving
- To deliver just CPAP – don't occlude valve and is continuous PIP with patients own resp effort

neoResus

The components of the Neopuff™

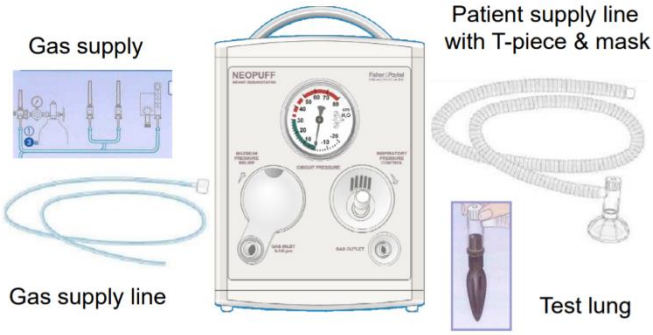

apls
Advanced Paediatric Life Support

Newborn life support

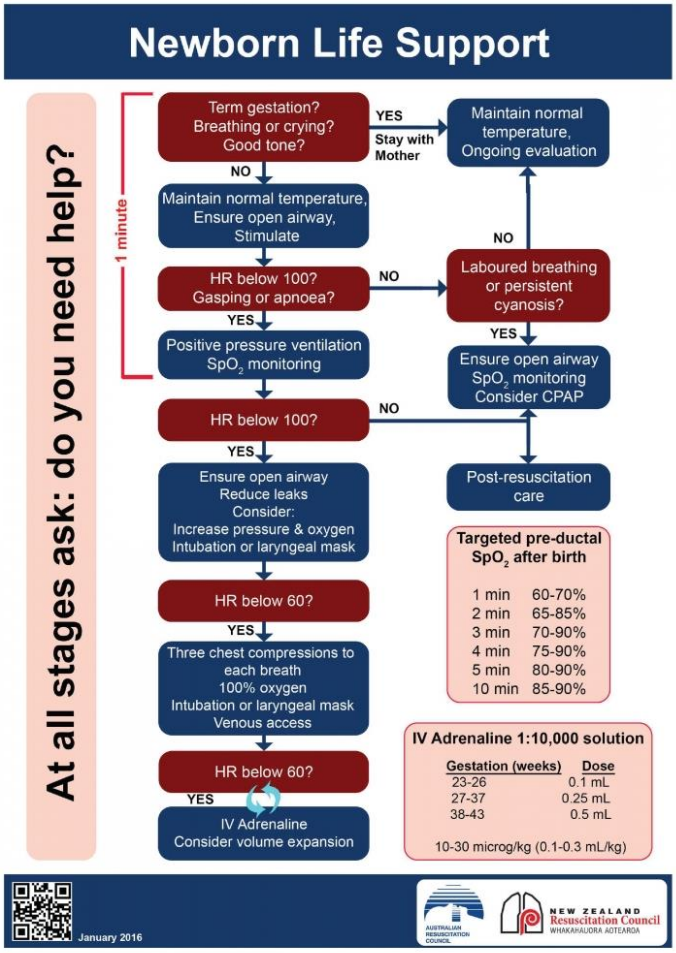

Chest drain by blunt dissection

- ✓ Indications
  - Main indication traumatic haemopneumothorax
  - Wide bore – doesn't clog and drains blood
  - Poss use otherwise pleural effusions, empyema or post op
  - Seldinger likely used in pneumothorax (vent, post tension without finger thoracostomy, failed asp, larger secondary pneumothorax)
  - Know BTS guidelines

- ✓ Contraindications
  - Patient wishes
  - Equipment, expertise
  - Coagulopathy
  - Infection over site – choose alt site

- ✓ Complications
  - Haemorrhage
  - Infection site/pleura
  - Pain
  - Cause pneumothorax
  - Visceral injury – liver/spleen/mediastinum

- ✓ Procedure
  - Time out to confirm indication and side including review of x-ray
  - Consent, Analgesia
  - Position – ideally 30 degrees head up with arm behind head (poss may need hand taping or someone to hold)
  - Safe triangle – 5th IC space, lat edge pec major anteriorly, lat edge latissimus dorsi posteriorly and anterior mid axillary line (to avoid long thoracic nerve)
  - Aseptic technique/skin prep
  - 1% lignocaine up to 3mg/kg
  - Horizontal incision parallel and above the rib below – avoid neurovasc bundle
  - Blunt dissection forceps to pleura
  - Finger sweep and leave finger in chest
  - Ensure tube is clamped and loaded onto curved forceps
  - Insert past finger until all eyelets inside chest
  - Attach underwater seal, unclamp tube
  - Suture and mesenteric dressing

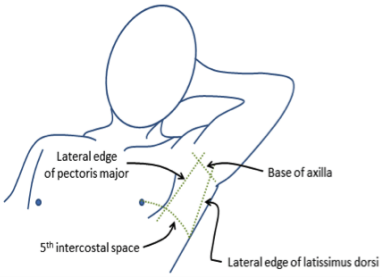

- ✓ Post procedure care
  - CXR and A to E assessment of patient
  - Document

- ✓ Instructions to nursing staff
  - Don't lift seal onto level of bed
  - Not to be clamped
  - Patient may need analgesia
  - If changes alert med staff

- ✓ Troubleshooting
  - Stops bubbling – ? emptied pneumothorax or poss blockage of tube
  - If increased bubbling – pneumothorax draining appropriately or air leak – check patient, tube, connections, drain
  - Swinging – will slow as pneumothorax is treated – negative intrathoracic pressure during inspiration

Underwater seal

- Previous examinations they have had several types of drain.
- Learn 1. Atrium most widely used Australia wide (see below)
- more likely to be asked the principles of underwater seals

3 chamber system

1- Collection
2- Water seal
3- Suction

1 – liquids drained

2 – gas drained – normally 2cm h20 pressure, prevents flow back into chest

3 – suction – attach suction from wall to chamber, if chamber is bubbling = suction is on. Regardless of wall settings will max suction the pressure of the bottle – normally set at 20cmh20. The chamber needs to be bubbling to work

Basically – stops air and fluid going back into the chest and allows for suctioning

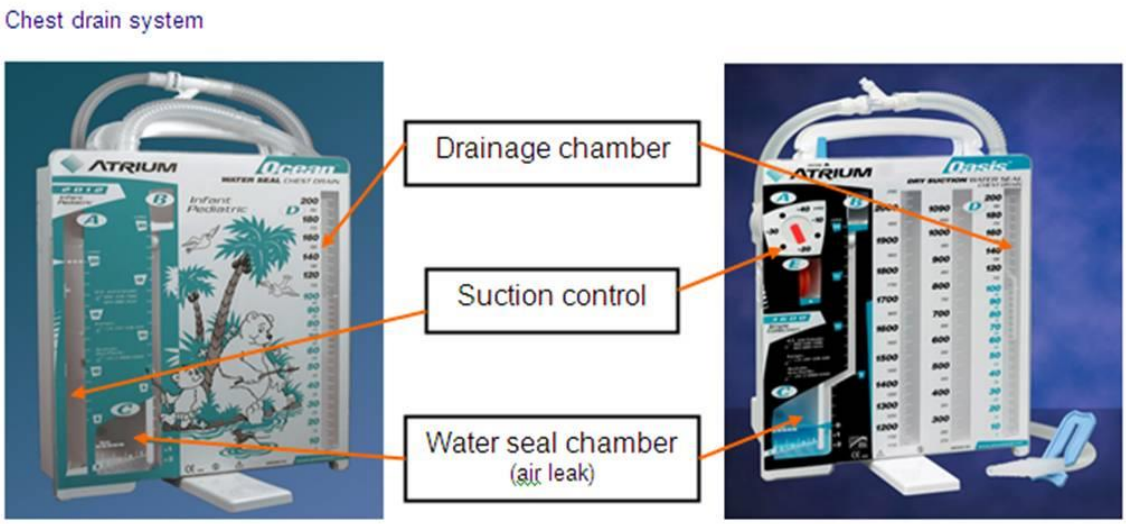

HFHNP oxygen

- ✓ Indications
  - Kids – low oxygenation and increased work of breathing e.g. bronchiolitis/pneumonia
  - Resp support infants and kids with chronic lung disease
  - Ongoing increased wob and low oxygenation despite supplemental o2
  - Weaning off cpap/bipap

- ✓ Contraindications (similar to NIV – anatomically top of head down)
  - Low GCS
  - Base of skull fracture
  - Facial trauma
  - Blocked nasal passages
  - Upper airway obstruction
  - pneumothorax
  - Asthma
  - apnoea's
  - abdo obstruction/vomiting

- ✓ complications
  - abdo distention
  - pressure areas
  - blockages secondary to secretions
  - pneumothorax

- ✓ equipment
  - 50% nostrils occlusions by nasal cannula
  - Humidifier
  - Flow
    - <16kg 2L/kg/min
    - >16kg – 30-50L/kg/min max 50L/min
  - <3y/o NG and 4 hourly aspirations or if patient has abdo distention

IO insertion

- Lifesaving in resus setting allowing quick and reliable vascular access

✓ Indications
- Rapid vascular access
- Drug/fluid/blood or blood products
- Nb – abdo trauma needs a humeral head IO

✓ Contraindications
- Fracture proximal to site
- Ischaemic extremity
- Local trauma/infection

✓ Complications
- Not in far enough – extravasc of whatever injected
- Pain needle insertion and with infusion flow
- Iatrogenic fracture
- Osteomyelitis/cellulitis
- n/v injury
- compartment syndrome

✓ equipment
- Aseptic technique/ PPE
- Poss 1% lignocaine if awake
- Skin cleaning
- EZ-IO kit
    - Paeds – pink 3-39kg
    - Blue – adult 40kg plus
    - Yellow obese or humeral IO
- Connection set – flushed normal saline

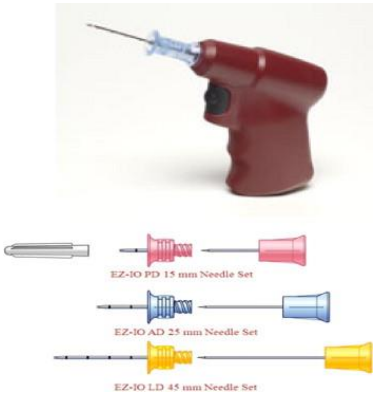

✓ procedure
- common sites
    - anteromedial surface of prox tibia – 2cm below and medial to tib tuberosity (kids 1cm)
    - proximal humerus – greater tubercle
    - distal medial tib – 3cm prox medical malleolus
    - others – distal femur – kids <8y/o, superior iliac crest, sternum – needs special needle

✓ for prox tibial
- Position – slightly flex knee for prox tib – don't put hand behind knee
- LA
- EZIO – blue
- Perpendicular to surface
- Press gently and drill steadily

- Angle away physeal plate
- Will give as breech cortex
- Remove trocar and check needle stable
- 10ml syringe and aspirate

✓ Post procedure care
- Connect IO and flush with normal saline
- No swelling should occur
- May need LA to be injected
- Use for 24 hours max

✓ Troubleshooting
- Poor correlation wcc, plt, co2, k, na, ca on bloods
- Each drug follow with 10ml normal saline flush
- Let lab know when sending samples that its marrow

Arterial line insertion

- ✓ Indications
  - Monitoring invasive BP
  - Repeated blood sapling/ABGs

- ✓ Contraindications
  - Local trauma/infection
  - Ischaemic extremity
  - Severe bleeding disorders
  - AV fistula

- ✓ Complications
  - Haematoma
  - Embolism/thrombosis – ischaemic limb
  - Accidental drug injection
  - Bleeding if disconnects
  - Line sepsis

- ✓ Procedure
  - Radial artery
  - Ulnar artery
  - Brachial artery
  - Dorsalis pedis
  - Femoral artery – resus/shock
  - Ultrasound if hypotensive, high bmi, oedema, vasc high freq probe, sterile probe cover and gel. Do inline cannulation

- ✓ Procedure for radial artery line insertion
  - Feel for radial arterial pulse
  - Allen's test – occlude both radial and ulna arteries – pump fist – let go ulna and palm should return to normal colour. Therefore, know collaterals working
  - Dorsiflex 45 degrees
  - Aseptic technique/clean/prep
  - LA bleb
  - 45 degrees to skin and feel pulse
  - Seldinger – needle, pulse, blood into chamber, advance wire and then catheter.
  - Nb don't let go of wire, stitch in line
  - Vs direct cannula insertion

- ✓ Post procedural care
  - Once in attach to extension, suture, dress, attach transducer and zero set up
  - Dispose of equipment, ensure comfort patient, document

CVC

- ✓ Indications
  - Therapeutic – drugs, tpn, temporary pacing, dialysis, fluid resus
  - Diagnostics – bloods
  - Monitoring – cvp, pul a catheter

- ✓ Contraindications
  - Infection site
  - Coagulopathy, low platelets
  - Difficult landmarks
  - Unco-operative/non consenting patient

- ✓ Complications
  - Early – arrythmia, art puncture, neck haematoma, air/lung embolism, pneumothorax, haemothorax, tamponade
  - Late – line sepsis, DVT

- ✓ Equipment
  - CVC – mx lumen, 15cm for neck/20cm for femoral
  - Continuous ecg monitoring, full sterile field/drapes

- ✓ Procedure
  - IJV
  - Subclavian v
  - Femoral v
  - USS – standard of care, high frequency vascular probe, sterile sheath and gel, USS for direct vision during procedure

- ✓ Internal jugular CVC
  - 20 degrees head down and supine patient
  - Extend neck and look to opposite side
  - Position head end, equipment lined up and can see ecg/uss
  - Prime/flush CVC with appropriate connectors
  - Aseptic technique, clean/prep/drape and local anaesthetic
  - Anatomical landmarks - Apex between the 2 heads SCM, lateral to pulse and aim ipsilateral nipple, low approach best but with USS best position can be found (In 20% artery is below the vein)
  - Needle and aspiration
  - Guidewire – to 10cm, Slide needle off/hold guidewire
  - USS to confirm guidewire in compressible and non-pulsatile vein
  - Scalpel and dilator
  - Catheter to 12-15cm (at/above carina)
  - Aspirate and flush all lumen and connections
  - Suture/dressing

- ✓ Post procedure
  - CXR
  - Document

- ✓ Other approaches
  - Subclavian – lateral and mid 1/3 clavicle and aim under clavicle
  - Femoral – 5 degrees head up, NAVY, 2cm below the mid-inguinal point, 1cm medical to pulse, 45 degrees towards umbilicus

DCCV

- ✓ indications – broad or narrow complex tachycardia and adverse symptoms
  - Shock
  - Syncope
  - CCF
  - MI
  - Or failed pharm rx

- ✓ Contraindications
  - Absent central pulse – CPR
  - No anticoag if AF of uncertain duration (in theory)
  - But if unstable needs a zap

- ✓ Complications
  - Pain if awake – therefore sedation and associated risk factors
  - R on T phenomenon – sync mode vip

- ✓ Equipment/staffing
  - Plan procedural sedation
  - Airway doctor, procedural doctor, nursing staff
  - Oxygen/suction, Iv access, cycling obs, ecg, sensing leads and defib
  - Pads
    - AP = apex and post – left infrascapular region
    - Lateral – Right side chest lateral sternum/below clavicle and then v5/6 position (lateral to apex)

- ✓ Procedure
  - Resus patient to best condition
  - Procedural sedation
  - Defib in Sync mode – normally 200J if unstable
  - 3 shocks then try diff position
  - Then 300mg amiodarone 20 min and repeat

- ✓ Post procedural care
  - A to E assessment

Tachycardia Algorithm (with pulse)

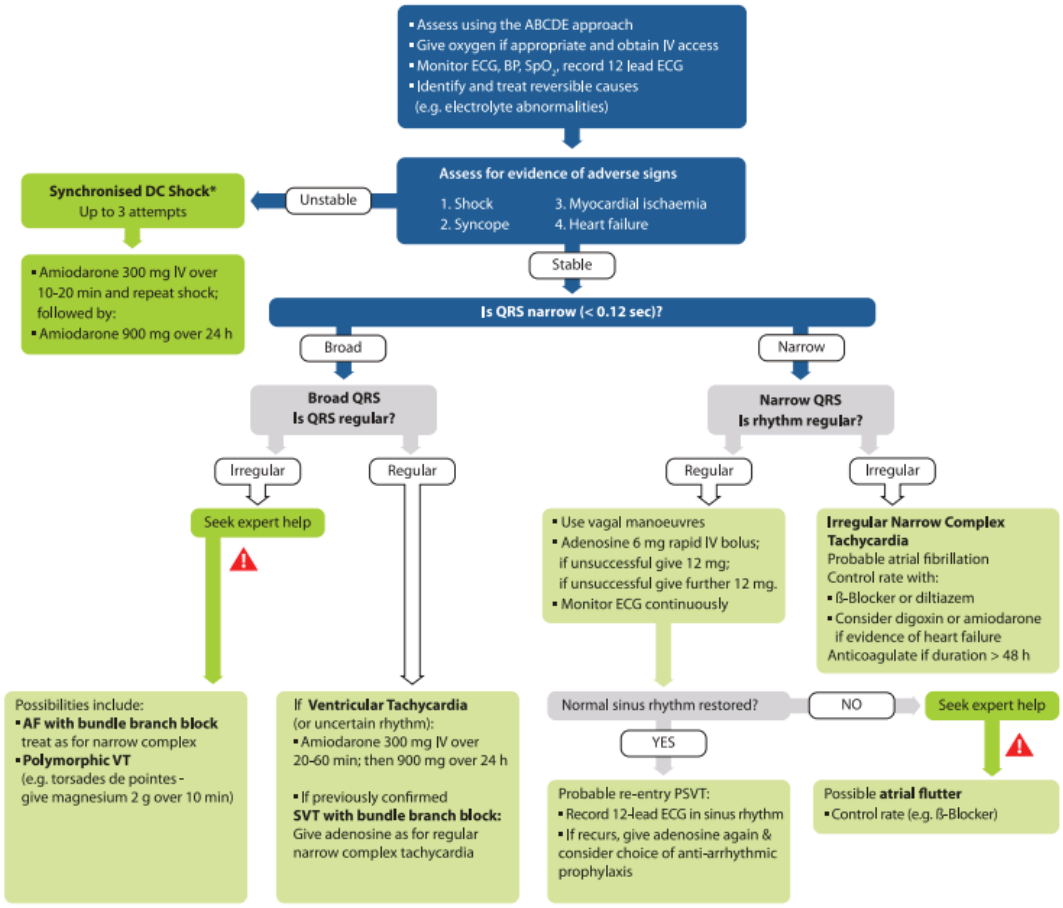

External pacing

- Temporary cardiac pacing using pads/paddles applied externally to chest

✓ Indications
- Bradycardia unresponsive to drug rx
- 3rd degree heart block
- Mobitz 2 with haemodynamic instability
- Overdrive pacing
- Asystole

✓ Contraindications
- CPR
- NFR etc

✓ Complications
- Failure to pace
- Failure to capture
- Discomfort

✓ Procedure
- Resus patient to best condition
- Equipment, staffing, drugs
- Bridging treatments – atropine, adrenaline/isoprenaline etc
- Analgesia/sedation – personal preference fent/midaz/ketamine + infusion as req
- AP pad placement with sensing wires
- Set in pacing mode
- Set rate 60-100bpm
- Set to 70mA
- Start pacing and increase until monitor capture
- Then check for clinical capture
- Increase 5-10mA or 10% above threshold

✓ Post procedural care
- Now arrange PPM, pacing wire, cath lab etc

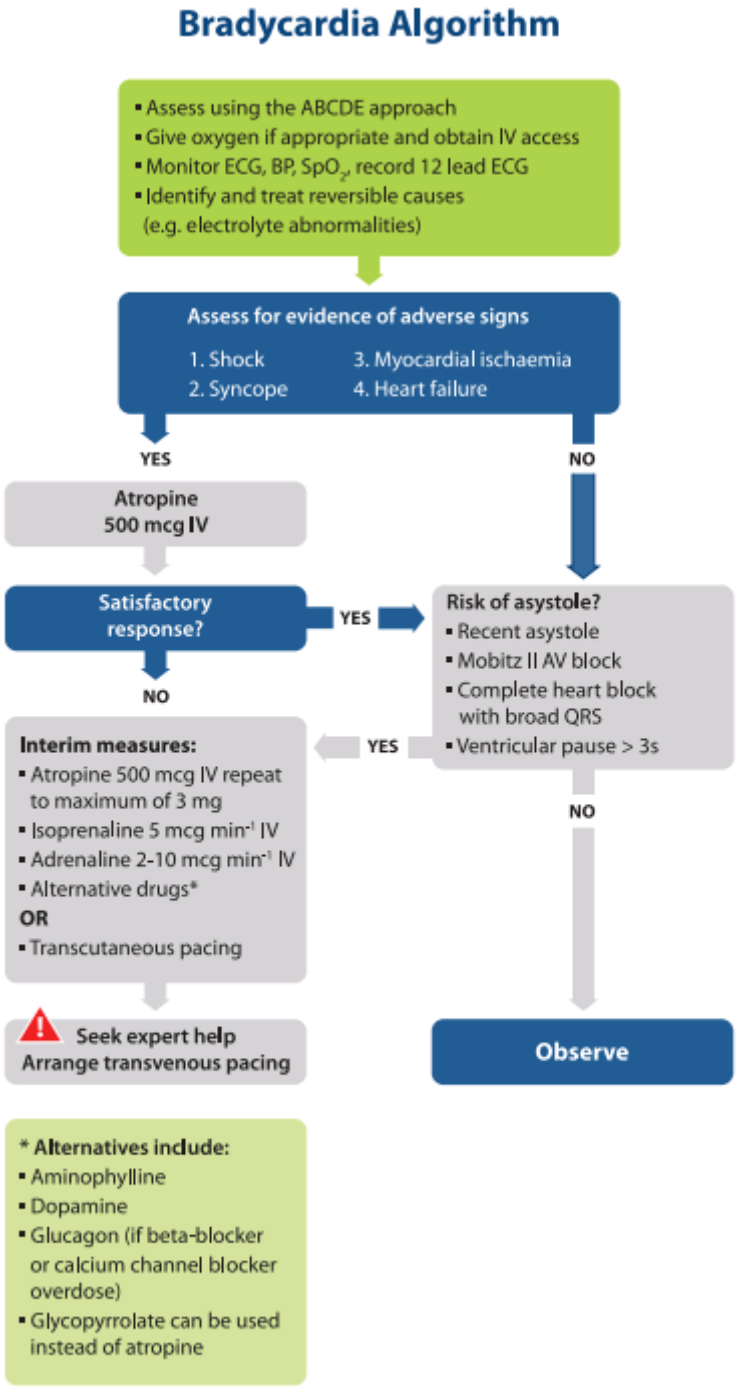

Fig. 1.9. Bradycardia algorithm. ABCDE – Airway, Breathing Circulation, Disability, Exposure; IV – intravenous; SpO_2 – oxygen saturation measured by pulse oximetry; BP – blood pressure; ECG – electrocardiogram; AV – atrioventricular.

Resus thoracotomy in ED

- last ditch attempt to save life of trauma patient
- traumatic arrest – no CPR, ETT, b/l finger thoracostomies, MTP then consider thoracotomy

✓ Indications
- Thoracic penetrating trauma – cardiac arrest with witnessed cardiac activity in the last 15 minutes
- Thoracic blunt trauma – cardiac arrest with witnessed cardiac activity in the last 10 minutes
- Refractory hypotension sbp <70 despite resuscitation – patient too unstable for transfer

✓ Why/what can you do
- Release pericardial tamponade
- Control cardiac haemorrhage/intra thoracic vasc bleeding
- Hilar swing to stop air embolus
- Cross clamp descending aorta
- Internal cardiac massage

✓ Contraindications
- CPR >10 min blunt and >15 min penetrating thoracic trauma
- Unsurviveable injury
- Asystole without tamponade
- No training/equipment/no cardiothoracics on site

✓ Complications
- Damage to surrounding structures
- Staff injury
- Infection
- Bleeding

✓ Equipment
- Suction/lights
- Thoracotomy tray
- Alert cardiothoracics

✓ Procedure
- Incision costo-sternal junction 5th intercostal space following around to mid axillary line
- Cut thought muscles and pleura with scissors
- Rib spreaders – handle into the axilla (Can extend with bone cutters to clamshell)
- Expose heart – forceps to separate sac and vertical incision avoiding phrenic nerve
- 'deliver the heart', evacuate clots and can start int cardiac massage (2 flat hands in a hinged clap)
- Int defib pads 15-20 joules
- Repair cardiac damage – foley, stitch or finger
- +/- hilar swing
- Cross clamp descending aorta

- ✓ Post procedural care
  - Theatre
  - ATLS continues
  - Family discussions
  - Documentation

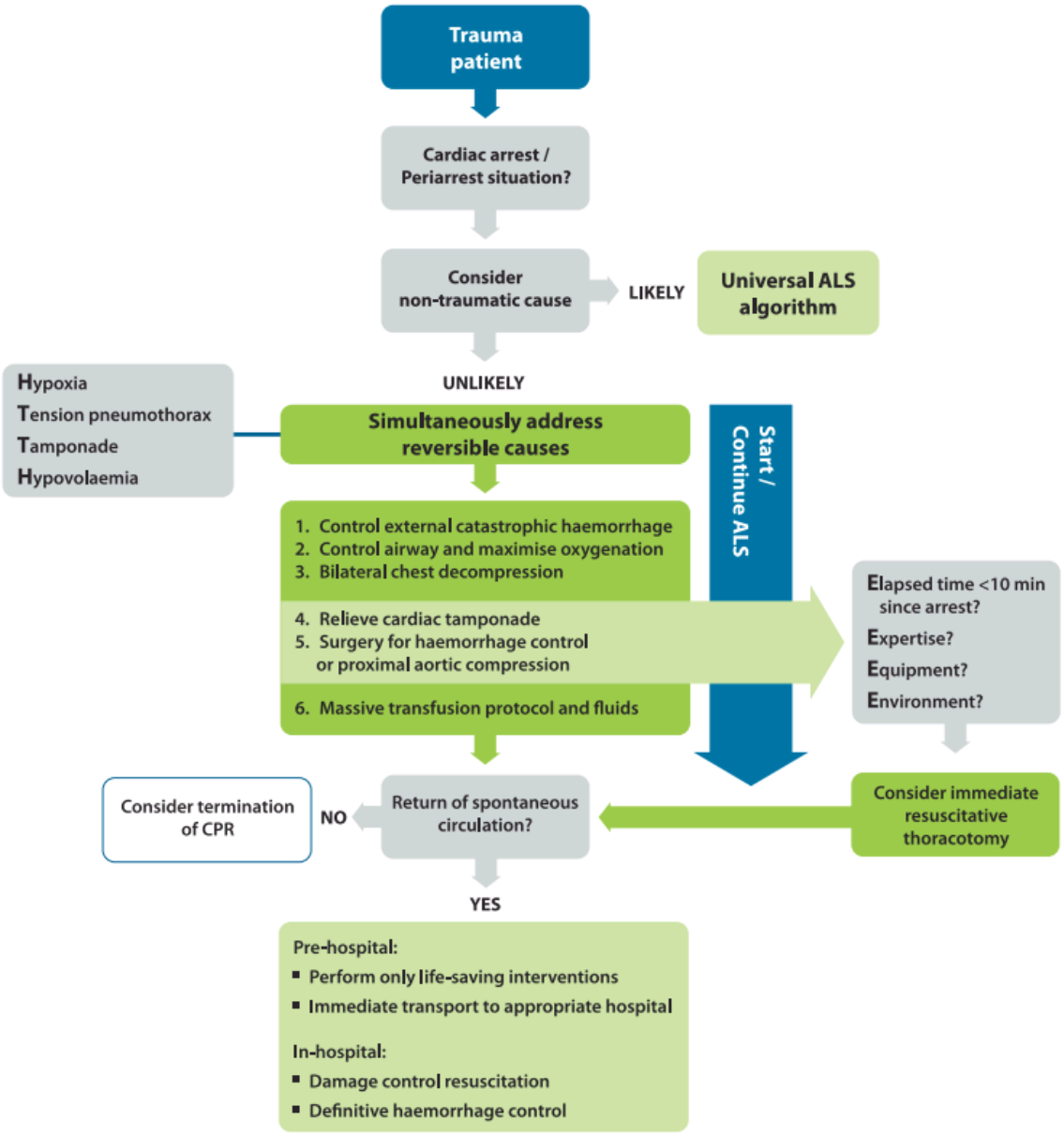

Fig. 1.11. Traumatic cardiac arrest algorithm.

Umbilical vein catheterisation

- Easiest/quickest way of getting central access in a neonate
- In ED used for emergency access only – aiming for aspiration of blood rather than above diaphragm in IVC as in PICU. Can be adjusted later.

✓ Indications
  - neonate requiring vascular access <10 days old
  - likely critically unwell or difficult peripheral access

✓ Contraindications
  - Infected/gangrenous stump

✓ Complications
  - Infection – local and systemic
  - Perforation
  - Bleeding
  - Air embolus
  - Portal vein thrombosis
  - Hepatic necrosis and portal hypertension

✓ Procedure
  - Sucrose and hold child still VIP
  - Umbi line kit or can use size 5 feeding tube if desperate
  - Prime line
  - Tie base of cord with a sterile cord tie or suture (loosely)
  - Clean stump with chlorhex/iodine
  - Cut stump to 1cm length with scalpel, identify vessels
  - Stabilize stump with forceps and insert catheter into vein 3-5cm until free-flowing blood can be aspirated
  - Aspirate and flush line with saline
  - Tighten umbilical tape to secure (possibly also allocate someone to hold it depending on situation)

C Spine Clearance

- ATLS A to E assessment and treat life threats
- Ask re pain and offer analgesia

- Mix of nexus and Canadian c spine – hx, examination

NEXUS

'NSAID' – any positive then CT c spine as test of adequate sensitivity

- N – neuro deficit
- S – spinal pain in the midline
- A – altered GCS
- I – intoxication
- D – disability

CANADIAN C SPINE

high risk mech = MAP – any positive scan

low risk = CARDS – all neg can continue to clinically clear + 45 degrees non painful lateral movement

- M – high risk mechanism of injury
- A – age >65 y/o
- P – paraesthesia

- C – c spine pain (no midline pain)
- A – ambulant at any time since
- R – rear ended
- D – delayed onset pain
- S – sitting in ED

- 45 degrees of movement laterally without pain

C Spine immobilisation

- Collar – unlikely question as currently practice moving away from hard collars and practice different across Australia – towels/tape vs Philadelphia collar etc

✓ Indications
- Trauma and concern for c spine injury
- Awaiting medical review or awaiting imaging

✓ Contraindications
- Relative - non-compliance – worsening of potential injury
- Remove precautions as soon as possible

✓ Complications
- Aspiration
- Pressure sores
- Missing injuries to back
- Loss of dignity
- Pain
- Increased ICP

✓ Procedure
- pick your approach and be able to explain – unlikely that you would be given a collar to fit

✓ Post procedural care
- Analgesia, antiemetics
- Remove jewellery
- Scan vs clearance as above

Closed Shoulder Reduction

ANTERIOR SHOULDER DISLOCATION

- ✓ Contraindications
  - Delayed >6 weeks presentation
  - Large humeral head defect
  - Displaced or multipart fracture/dislocations – operative open rx

- ✓ Complications
  - Recurrent dislocations
  - Bony injury (can cause hillsachs or banksart)
  - Axillary nerve injury
  - Axillary artery rupture
  - Rotator cuff tear

- ✓ Procedures
  - Pick 2-3 reduction techniques and know them well
  - Have a logical approach including analgesia, nitrous, sedation etc

- ✓ Post procedural care
  - Discharge after successful reduction
  - Maintain in shoulder immobilizer until seen in follow-up by orthopaedic surgery

POSTERIOR SHOULDER DISLOCATION

- ✓ Contraindications
  - same as anterior but neurovasc injuries and rotator cuff tears less common

- ✓ Complications
  - same as anterior
  - Don't reduce chronic >4 weeks as risk of arterial injury – ortho for open reduction

- ✓ Procedure
  - Most require procedural sedation
  - Adduct arm
  - Traction along long axis of humerus
  - Have assistant push humeral head anteriorly into glenoid fossa
  - Apply shoulder immobilisation

- ✓ Post procedural care
  - Ortho outpatient follow up
  - Unless >4 weeks chronic then admit for closed reduction as above

Hip Reduction

- Ortho emergency – reduction native hip <6 hrs – risk avasc necrosis
- Prosthetic more common and less emergent
- Posterior - 90% and often associated acetabular fracture – shortened, int rotated, adducted, sciatic nerve compromise possible
- Anterior – 10% and neurovasc compromise unusual – extended (sup) or flexed (inf), externally rotated, adducted

✓ Contraindications
- Femoral neck fracture
- Open traumatic – straight to OT
- 3 failed reduction attempts needs to go to OT

✓ Complications
- Fractures associated with the force of the reduction (or movement of pre-existing fragments)
- Soft tissue injury
- Reduction normally relieves sciatic nerve impingement but symptoms can persist

✓ Procedure
- Posterior – captain morgan, Allis maneuver, wadell – again pick one and know it well
- Captain morgan
    - Your knee behind supine patients flexed knee with anterior force lifting (via provider plantar flexing foot) and rotation as needed
    - Successful in patients with prosthetic hips as well
    - Poses less risk of knee injury since most force is applied by lifting leg rather than applying leverage at knee
    - Less risk to provider who does not have to stand on top of gurney, and requires only one provider
- Anterior - traction, internal rotation, and then external rotation once the femoral hip clears the acetabular rim

✓ Post procedural care
- Check sciatic nerve function – toe extension for EHL
- Document procedure
- If reduced outpatient ortho f/u
- Maintain dislocation precautions
- Don't bend past 90 degrees – zimmer splint can help this
- Don't cross midline of body (hip abduction pillow)
- Don't rotate operated leg inward
- In bed toe and kneecap to ceiling
- Toe touch/min weight bearing

Femoral traction splints

- Has been asked before – "explain the principle of femoral traction splints"- no splint in the room
- Likely to use with femoral nerve blocks

✓ Indications
- Femoral shaft fracture
- Reduction of fracture improves pain
- Reduces blood loss
- Reduces nerve damage
- Reduces swelling
- Closed or open fracture

✓ Contraindications
- Lack of equipment or education
- Unstable patient in the field
- Other fracture of the leg/pelvis

✓ Complications
- Pressure damage to buttocks/strapping/skin
- Malalignment of fracture
- Neurovascular compromise
- Pain

✓ Procedure –
- Sager, thomas, donway etc etc there are loads – pick your fav and be able to explain briefly
- Sits against buttocks/perineum
- Straps to keep in place
- Some way of extending the length from perineum to foot with traction

✓ Post procedure care
- Assess neurovasc status – if loss pulses remove splint
- Analgesia/femoral nerve block
- Ortho referral/trauma centre

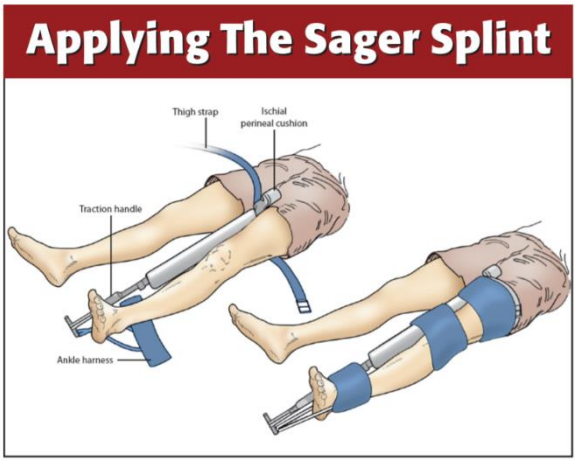

Pelvic binder application

- ✓ Mx devices and ways of doing it – unlikely to have binder in room (similar to femoral splint)

- ✓ Indications
  - Any trauma patient with poss pelvic injury
  - To prevent re-injury from pelvic movement
  - Decrease pelvic volume
  - Tamponade bleeding bones/vessels
  - Reduced pain
  - Controversial in lateral compression fractures – as a general rule – apply binder and If patient deteriorates then remove

- ✓ Contraindications
  - Controversial in lateral compression fractures

- ✓ Complications
  - Worsening haemodynamics if better pelvic alignment isn't managed or disruption of clot
  - Depending on splint type - reduced visualisation/access abdo and femoral area (efast/access)
  - Covering/hiding other injuries ant/post

- ✓ Procedure
  - VIP – level of the greater trochanters and aiming for approx. normal anatomy
  - Sam sling, t pod, can use simple sheet (ortho - anterior ex fix, c clamp) – pick one and be able to explain briefly

- ✓ Post procedural care
  - Analgesia/antiemetics
  - Imaging – trauma series +/- CT
  - If patient deteriorates on application consider removal

Knee aspiration

- ✓ Indications
  - To exclude septic arthritis
  - Diagnose effusion of knee

- ✓ Contraindications
  - Cellulitis over site
  - Metalwork in joint
  - Coagulopathy
  - Pt refusal

- ✓ Complications
  - Introduce infection
  - Bleeding into joint
  - Pain
  - Damage to articular cartilage

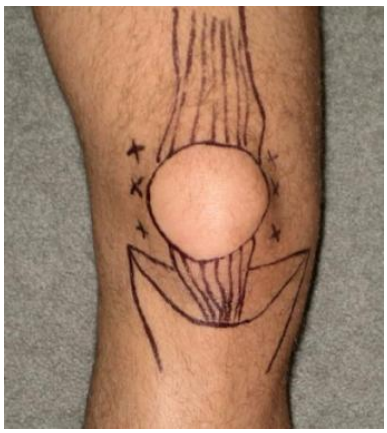

- ✓ Procedure
  - Verbal consent
  - Medial or lateral approach
  - Knee in extension and confirm effusion clinically
  - 2cm lateral or medical to side of patella (sup lat or medial)
  - Aseptic technique, clean, drape
  - 1% lignocaine to skin
  - Green needle
  - Aim inferior medially and into joint, aspirating as going – avoid cartilage
  - Aspirate as much as poss
  - Remove needle and band aid

- ✓ Post procedural care
  - Sent for cell counts, gram stain, crystals and culture
  - Documentation
  - Referral likely dependant on aspiration results

Suprapubic aspiration in infants

- Gold standard urine collection <2 y/o
- Safe/simple
- Ultrasound increases success
- Any growth on urine is significant
- Do prior to LP/bloods as likely to pee during those procedures

✓ Indications
- Septic workup and cant delay antibiotics for a clean catch
- <2 y/o and important to confirm uti e.g recurrent utis
- On prophylactic antibiotics or unusual utis

✓ Contraindications
- Bleeding
- Abdo distention
- Massive organomegaly
- Urogenital/gi abnormality
- Overlying cellulitis

✓ Complications
- Micro haematuria common
- Bladder haematoma/haemorrhage
- Perforation of bladder/bowel
- Intra abdo organ damage (unlikely)

✓ Procedure
- Consent parents
- Shouldn't have pu'd 30 min prior and should have >20mls on bladder scan/USS
- Topical emla/anaesthetic/sucrose <3 months
- Ensure kid held firmly (not by parent) – legs extended and together'
- Be able to catch urethral urine sample if patient pu's during (?occlude penis/urethra in boys to avoid this?!)
- Aseptic technique/Wipe lower abdo with alcohol swab
- Blue needle
- Insert needle perpendicular to skin
- Puncture quickly like a popping balloon
- Insert to hub of needle and aspirate as pulling back
- Don't aim into pelvis
- If unsuccessful pull back and keep tip under skin and aim further out of pelvis
- Otherwise continue po fluids and retry/in and out/clean catch as required
-

SP catheter insertion

- ✓ Indications
  - Urethral disruption secondary to trauma
  - Severe urethral stricture or complex prostatic disease

- ✓ Contraindications
  - Empty/unidentifiable bladder
  - Bowel anterior to bladder
  - No consent

- ✓ Complications
  - Bowel perforation
  - Through and through injury with damage to rectum, vagina, uterus
  - Intraperitoneal extravasation
  - Infection
  - Haematoma/haemorrhage
  - Haematuria

- ✓ Equipment
  - Bonnano SP kit, Cook peel away kit or CVC kit
  - In principle need a needle, guidewire, dilator, catheter

- ✓ Procedure
  - USS to mark/locate bladder/know how far from skin to bladder
  - Aseptic technique
  - Prep skin and local anaesthetic
  - Skin wheal and subcut/muscular

- ✓ Bonnano
  - Straighten out the curl with the plastic sheath to enable passage of trocar
  - Insert trocar being careful not to catch edges of sheath
  - Remove outer rigid plastic sheath
  - Know depth to bladder
  - Insert perpendicular to skin and look at marks on catheter – prob stop after insertion approx. 5cm (depending on uss findings)
  - Now hold trocar steady and slide catheter off it and into the bladder
  - Trocar out
  - Stitch with LA
  - Luer lock adapter can be attached
  - https://www.youtube.com/watch?v=IzTUvS8Aetg

Femoral nerve block

- ✓ indications
  - Quick and effective analgesia for femur fractures
  - Facilitate application traction/splint
  - Femoral shaft fractures or NOF

- ✓ Contraindications
  - No consent
  - Allergy local anaesthetics
  - Overlying skin infection
  - Relative – anticoagulation

- ✓ Complications
  - Failure
  - Iv injection with toxicity
  - haemorrhage/haematoma
  - Intraneural injury

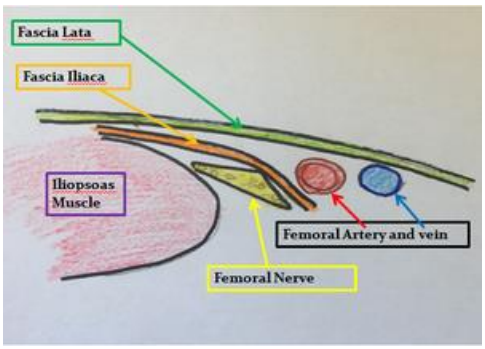

- ✓ Equipment
  - USS – linear transducer, nerve preset
  - Ropivacaine 0.75% 20mls (max 3ml/kg)
  - >12 y/o 20mls, under 12 y/o 0.25ml/kg
  - Probe cover
  - Sonoplex needle

- ✓ Procedure
  - Consent
  - Anatomy NAVY - vessels inside sheath and nerve outside
  - Landmarks – pulse at inguinal ligament (between pubic tubercle and asis), 1cm lateral and distal to pulse
  - Confirm correct side
  - aseptic technique, PPE, drape
  - position - Lie patient as flat as poss, ext rotation leg
  - small amount of LA to skin and s/c at needle entry site
  - USS guidance to femoral nerve sheath – aspirate and then 20ml around nerve

- ✓ Post procedural care
  - Dress site
  - Disposition

Biers block

- ✓ Indication
  - Manipulation of wrist/forearm fracture (can be used on lower limb also)
  - Clean and repair multiple lacerations of forearm
  - Remove foreign body
  - Procedural sedation not possible/too risky/not fasted

- ✓ Contraindications
  - Severe hypertension >180 systolic
  - Uncooperative patient
  - Compartment syndrome
  - Allergy to local anaesthetic
  - Methemoglobinemia
  - Peripheral vascular disease
  - Sickle cell
  - Pregnancy/lactation
  - Not possible to site distal access

- ✓ Complications
  - Local anaesthetic toxicity – dizziness, tingling, seizures and arrythmias
  - Methemoglobinemia – hypoxia, cyanosis, shortness of breath, confusion, sats unreliable
  - Cardiac arrest

- ✓ Equipment
  - Prilocaine 0.5% 3mg/kg
  - Midazolam
  - Intralipid 20% 1ml/kg bolus +/- infusion
  - Methylene blue 1% 1mg/kg
  - Check cuffs

- ✓ Procedure
  - 2 cannulas 1 distal to injury and 1 contralateral side
  - Elevate/exsanguate limb
  - Apply cuffs – distal inflated first at 100mmhg over systolic bp
  - Inject LA into cannula in distal affected arm
  - Mottling of skin and in 5-10 min will be anesthetised
  - Then inflate proximal cuff (now over anaesthetised skin) and deflate distal cuff
  - Do procedure/xrays etc
  - Max inflation time 40-45 min and minimum 25 min (after that prilocaine is tissue bound)
  - Deflation of cuff – straight down vs intermittent on/off

- ✓ Post procedural care
  - Documentation
  - Observe for tox 1 hr post procedure and keep second cannula in until then

Regional nerve blocks

- Mx options type of local anaesthetics – safe doses lignocaine <3mg/kg without adrenaline

✓ Indications
- Repair of injury or removal of foreign body in nerve distribution
- Regional pain control
- Doesn't distort anatomy

✓ Contraindications
- Infection
- Allergy
- Lack of patient cooperation

✓ Complications
- Bleeding
- Haematoma
- Infection
- Intravasc injection
- Swelling
- Allergy
- Nerve/vessel damage

✓ Procedure
- Infraorbital nerve block
- Mental nerve block
- Median nerve block
- Post tibial nerve block

✓ Infraorbital block
- intraoral approach
- Lower eyelid, face, upper lip, teeth
- Look ahead – line pupil and move down to infraorbital ridge
- Keep finger there
- Q tip with lignocaine on to 2nd premolar on side for 1 min
- Buccal mucosa and up to finger – 1.5-2cm
- Aspiration and 2-5ml

✓ Mental block
- Buccal mucosa between 2 lower premolars

- ✓ Median nerve block
  - 1-2cm prob to palmar crease
  - Between palmaris longus and flexor carpi radialis
  - 5ml

- ✓ Post tibial block – sole of foot
  - Medial ankle
  - Medial malleolus and achilles
  - Nerve behind artery
  - Half way between the malleolus and achilles
  - Level of upper edge of the medical malleolus
  - 2-4ml

https://www.wikem.org/wiki/Nerve_and_regional_blocks_(main)

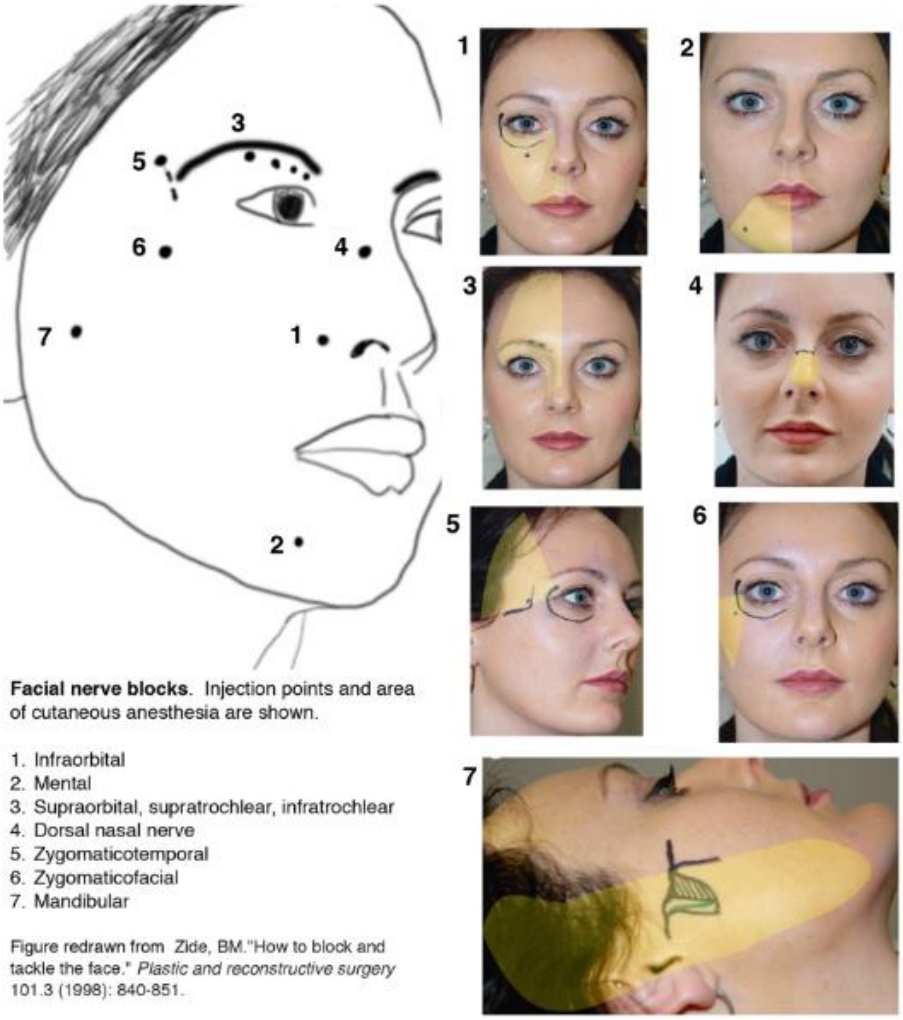

Facial nerve blocks. Injection points and area of cutaneous anesthesia are shown.

1. Infraorbital
2. Mental
3. Supraorbital, supratrochlear, infratrochlear
4. Dorsal nasal nerve
5. Zygomaticotemporal
6. Zygomaticofacial
7. Mandibular

Figure redrawn from Zide, BM."How to block and tackle the face." *Plastic and reconstructive surgery* 101.3 (1998): 840-851.

Facial nerve blocks are typically performed by landmark with a high rate of success and aid greatly in the repair of complex lacerations that might otherwise be distorted by direct wound infiltration. (Figures reproduced from Prendergast, Peter M. "Local Regional Anesthesia." *Aesthetic Medicine* (2011): 87-101.)

Feeling Blocked? Another Pain Management Tool in the Emergency Department

Wilson, 2018 - Annals of EM

Upper Extremities	
Digital	Finger laceration, paronychia, nail removal, dislocation/ fracture
Radial	Distal radius fracture
Ulnar	Boxers fracture, ulnar surface of hand, 5th digit injury
Median	Laceration lateral palm - 1/2/3/4 (medial) finger injury, thenar eminence
Lower Extremities	
Posterior Tibial	Calcaneal fracture, foreign body/laceration to sole of foot
Sciatic	Ankle dislocation, achilles tendon rupture
Superficial Peroneal	Dorsal lateral foot
Femoral	Hip/femoral fractures, patellar subluxation, tibia fractures, anteromedial thigh lacs
Head/Neck	
Supra-orbital/-trochlear	Entire forehead from scalp vertex to bridge of nose
Greater Occipital	Laceration to posterior half of scalp, migraines
Superficial Cervical	Clavicle fracture, IJ central line, submandibular abscess, lateral neck laceration
Greater Auricular	Laceration/abscess to ear lobe/helix
Trunk	
Supraclavicular plexus	Elbow or wrist dislocation
Suprascapular	Shoulder dislocation, adhesive capsulitis
Transverse Abdominal	Pre-procedural abdominal surgery
Intercostal	Chest tube placement Isolated rib fracture
Dorsal Penile	Priapism, Paraphimosis

Anesthetic *	Dose (mg/kg)	Max (mg)	Duration (h)
Lidocaine (w/epi)	7	500	1.5 - 3
Lidocaine (w/o epi)	4.5	300	1 - 2
Bupivicaine (w/epi)	3	225	5 - 8
Bupivicaine (w/o epi)	2.5	175	3 - 6
Chloroprocaine (w/epi)	14	1,000	0.5 - 1
Chloroprocaine (w/o epi)	11	800	0.5 - 1
Ropivicaine (w/epi)	3.5	225	3 - 6
Ropivicaine (w/o epi)	3	225	3 - 6

*courtesy of painmedpsa.org

Ex: : 1% lidocaine = 10mg/cc; 7 mg/kg x 70 kg patient = 490 mg; 490mg @ 10mg/cc = 49 cc 1% lidocaine

Local Anesthetic Systemic Toxicity (LAST)

1.5 cc/kg bolus IV intralipid (20%) over1 min

@PainProfiles

Ketamine sedation

- ✓ Indications
  - Short painful procedures in children
  - Suturing
  - Removal fb nose/ears
  - Manipulation closed fracture
  - Normally in >12 months and otherwise well/fasted

- ✓ Contraindications
  - Altered GCS
  - Allergy
  - URTIs
  - Congenital cardiac disease
  - Airway deformity/surgery
  - Post pharyngeal/laryngeal/anal operations
  - Uncontrolled vomiting
  - Uncontrolled seizures
  - Thyroid disease

- ✓ Complications
  - Laryngospasm
  - Apnoea's
  - Vomiting
  - Invol movements
  - Nystagmus
  - Emergency phenomena

- ✓ Equipment
  - Monitoring /airway trolley/staffing etc etc emla
  - Ketamine 1mg/kg iv and 0.5mg top ups
  - Ketamine 4mg IM and 2mg top ups
  - Propofol 1mg/kg and sux 1mg/kg for rx laryngospasm

- ✓ Procedure
  - Consent, confirm fasting, clarify risk complications
  - Monitoring and precautions
  - Dissociate anaesthesia, Eyes open, Twitch/move/drool
  - Emergency phenomena – dim lights, min stimulation etc (not evidence based)
  - Common unsteady for 1 hr post +/- vomit

- ✓ Post procedural care
  - Document
  - Observe until patient has normal cognitive state, no nystagmus, can sit and walk normally, Tolerating po fluids
  - Discharge with appropriate advice and sensible carer

Escharotomy

- Roman breast plate/chest/neck/limbs

✓ Indications
- Circumferential burns chest – impairs ventilation
- Constrictive neck burns and airway concerns
- Circumferential burns extremities – once reduced circulation but before pulses lost

✓ Contraindications
- Not the above
- DNR etc
- Other Unsurviveable injuries

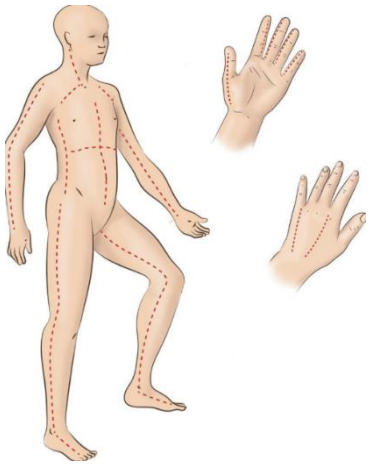

✓ Complications
- Nerve and vessel damage
- Bleeding
- Infections
- Ulnar nerve – Infront of medial epicondyle
- Peroneal nerve – over neck of fibula
- Long saphenous vessels – behind medial malleolus

✓ Complications of Inadequate escharotomy
- Local – tissue necrosis, amputation, airway obstruction, compartment syndrome
- Systemic – rhabdo, AKI, hyperkalaemia, hagma

✓ Procedure
- Normally in OT but poss in ED/field
- Clean/aseptic technique
- Use marker to define intended lines
- Eschar insensate
- Prep for blood loss – ties, topical haemostat
- Cut to subcutaneous fat and go to at least 1cm onto 'normal' viable skin each end
- Trunk – ant axillary lines from clavicle to RIF/LIF, join at pubic margin, costal margin & collar bones then final sternal cut
- Limbs – mid axial lines between ext & flexor surfaces, avoid flexor creases
- Neck – sides of neck posterior to vessels

LP adults and kids

- ✓ Indications
  - CSF for investigation – meningitis, encephalitis, SAH, Guillain-Barre
  - Measure opening pressures

- ✓ Contraindications
  - Reduced GCS, coma
  - Signs of increased ICP – focal neuro, papilledema, bulging fontanelle
  - Shock/unstable patient
  - Seizure
  - Coagulopathy/low platelets <25
  - Local cellulitis over site of insertion
  - Rx if can't LP – dex and antibiotics if older than 2 months
  - Consider CT prior to LP if concerns but normal CT doesn't avoid coning

- ✓ Complications
  - Failure
  - Post dural headache
  - Numbness legs
  - Resp issues positioning
  - Spinal haematoma/abscess

- ✓ Equipment
  - Analgesia/sedation/nitrous, EMLA/lignocaine, <3/12 old sucrose
  - LP pack – age specific+/- manometry
  - Aseptic technique
  - Pencil point needle reduces risk headache in adults– 22-25g
  - Bevelled needle with stylet in kids – 22-25g – depth as per age

- ✓ Procedure adults
  - Position – pick your choice – left lateral vs epidural position (can't do pressures in epidural)
  - Line iliac crests l3-4, conus ends at L1/2 adults
  - LP midline and bevel up, aim for umbilicus
  - 3 pots 10 drops each
  - Reinsert introducer if using and remove needle with pressure/band aid to site post removal
- ✓ Procedure kids
  - Foetal position, back 90 degrees to bed, hips and shoulders in line
  - Most VIP is an experienced staff member to hold patient in position
  - Check o2 sats throughout as risk airway obstruction with position
  - Aim for L4/5 or lower (no higher as conus ends at L3 at birth)
  - Otherwise same as adults – quick piercing skin and wait for them to stop wiggling

- ✓ Post procedural Care
  - Sent CSF for interpretation - Cell count, mc&s, gram stain, glucose, protein, xanthochromia
  - Document

Foreign body nose

- +ve pressure
- Removal with equipment
- ENT/surgery

- +ve p
  - BVM
  - Big kiss
  - Blow nose

- Instrumentation
  - R angle hook
  - Katz catheter
  - Suction
  - Glue on a stick

- Then ENT/OT

✓ Complications
  - Trauma
  - Bleeding
  - Aspiration

Epistaxis – nasal packing

- ✓ Indications
  - To control epistaxis

- ✓ Contraindications
  - Base of skull fracture

- ✓ Complications
  - Pain/discomfort
  - Trauma to nasal mucosa
  - Infection with pack left in – augmentin duo forte

- ✓ Equipment
  - PPE
  - Head torch
  - Suction
  - Lignocaine with adrenaline/Cophenylcaine
  - Nasal speculum
  - Silver nitrite cautery
  - Rapid rhino ant/post (double lumen)
  - Other option for post – foley and BIPP

- ✓ Procedure
  - Verbal consent
  - Sit up and suction nose gently
  - Spray with cophynylcaine +/- soaked pledget cotton wool
  - Pinch nose and first aid for 15 min
  - 90% ant septum/littles area, try and find bleeding point to cauterise
  - Ongoing bleeding – soak rapid rhino in sterile water and insert horizontally alongside septum, inflate with air and tape in place
  - +/- pack other side if ongoing bleeding

- ✓ Additional management
  - A to E assessment
  - 2x large proximal iv access
  - Tranexamic acid
  - MTP if req etc

- ✓ Post procedural care
  - ENT/theatre/embolization as required if ongoing bleeding
  - Disposition – inpatient or early outpatient follow up if bleeding controlled
  - Documentation

TMJ reduction

- Normally anterior – extreme mouth opening – yawning, eating, dental op
- Traumatic – normally superior and posterior dislocation
- Normally bilateral
- o/e if anterior then palpation of TMJ can reveal 1 or both ant displaced condyles
- if clinically subtle or traumatic – OPG/CT

✓ Indications
- TMJ dislocation – unilateral/bilateral/acute/chronic

✓ Contraindications
- Mandibular fractures
- Extensive facial trauma
- Multiple prior unsuccessful attempts

✓ Complications
- Injury to practitioner
- Damage to teeth/oral prosthesis
- Fracture of mandibular condyle
- Complications of sedation
- Damage facial nerve
- Delayed reduction – fibro-osseous ankylosis

✓ Procedure
- Analgesia +/- procedural sedation if ++ spasm
- Syringe technique
    - Place 10ml syringe between upper and lower post molars
    - ask them to roll it backward and forward
- Manual reduction
    - thumbs in inf molars (gauze wrapped)
    - down and backwards pressure
    - have someone hold patients head
-

✓ post procedural care
- soft foods 1/52
- avoid extreme mouth opening
- follow up ENT/max fax
- chronic dislocations surgery/fix

Lateral canthotomy

- ✓ Indication
  - Suspected acute orbital compartment syndrome with reduced visual acuity
  - Intraocular pressure 40+ or difficult globe compression
  - Proptosis
  - Causes include retrobulbar haematoma, bleed, tumour, abscess

- ✓ Contraindications
  - Globe rupture

- ✓ Complications
  - Incomplete
  - Iatrogenic – globe/structure injury
  - Loss adequate lower lid suspension
  - Bleeding
  - Infection

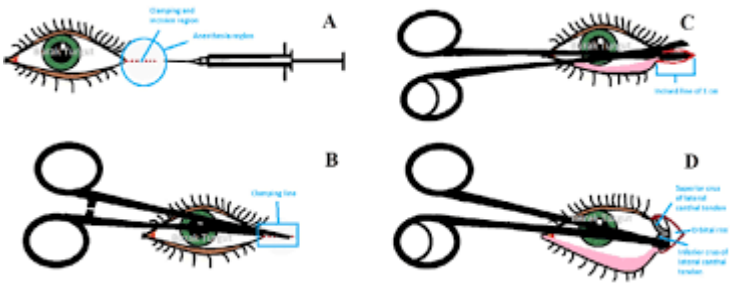

- ✓ Procedure
  - Consent
  - +/- sedation
  - Aseptic technique, clean skin chlorhex
  - LA to lateral canthus to rim of orbit – needle out to bone
  - Irrigate eye
  - Compress skin horizontally for 1 min with mosquito haemostat
  - Then cut skin laterally with iris scissors
  - Grasp lower eyelid – retract, strum ligament and cut
  - If still too much pressure do superior canthal ligament also

- ✓ Post procedural care
  - Refer to opthal

eFAST

- Primary survey trauma patients – that are UNSTABLE
- Free fluid abdo, pneumothorax/haemothorax or tamponade
- Expedites intervention
- Fluid black

✓ Indications
  - Unstable trauma

✓ Contraindication
  - No contraindications but if the patient is stable regardless of eFAST should have CT scan

✓ Pros
  - Unstable/bedside
  - Portable
  - Quick/easy/non invasive
  - Repeatable
  - Increased spec

✓ Cons
  - Can't r/o pathology
  - Doesn't identify organ/site of bleeding
  - Can't distinguish between blood and other fluids
  - Can be technically difficult
  - Can't see retroperitoneum
  - False neg – obesity, subcut emphysema
  - False positive – epicardial fat pad, ascites, pre-existing pleural or pericardial fluid

✓ Equipment
  - PPE
  - USS gel
  - Probe cover

✓ Procedure
  - Pt supine
  - Marker of probe to head/RHS of patient
  - 5 views
    - RUQ – mid axillary line RHS level xiphisternum and slightly post
    - LUQ – similar position on left – more post and slightly higher
    - Subcoastal – subxiphoid cardiac view
    - Pelvic – 1-2cm above pubis and down
    - Ant pleural – 5-8 b/l midclavicular line looking for lung sliding

PIB application

- ✓ Indications
  - all Australian venomous snakes
  - funnel webs
  - blue ring octopus
  -
- ✓ No contraindications

- ✓ Procedure
  - Broad pressure bandage 10-15cm wide elastic better than crepe
  - Apply over bite site asap
  - Then bandage distal to bite before moving proximal with as much of the limb bandaged as possible
  - Over clothing
  - So tight you can't get a finger underneath
  - Splint and joint above and joint below to restrict limb movement
  - Upper limb put in a sling
  - Call for help
  - Keep pt still/lying flat

- ✓ Summary
  - Bandage site
  - Then distal to prox
  - Splint
  - Call for help

EXTRA

EpiPen education prior to discharge

- ✓ Indications for use/symptoms
  - Mouth - Itch/swelling tongue and lips
  - Throat – itch/tight/hoarse
  - Skin – itchy/hives/red/swelling
  - Gut – vomiting, diorrhea, cramps
  - Lung – sob, cough, wheeze
  - Heart – weak pulse, dizzy, pass out
  - Only few symp may be present – act fast

- ✓ How to use the EpiPen
  - Lie down
  - Call for help/000
  - Remove trigger if possible
  - Pull off blue safety cap
  - Hold in fist
  - Hold against thigh – can do it through clothes
  - Push down hard until click and hold for 3 sec
  - Ambo to ED
  - Can use 5 min later if no improvement in symptoms (ensure ambo on way)
  - 'Blue to the sky and orange to the thigh'

- ✓ Discharge advice
  - Keep for 4-6 hrs post adrenaline (+/- cardiac monitor)
  - Education – video and practice with EpiPen trainer
  - Discharge info for GP (+/- prednisolone/antihistamine 3 days)
  - Given patient copy anaphylaxis management plan
  - Avoidance of triggers if possible
  - Immunology f/u
  - Home with EpiPen/script – advise 1 for school/work etc