

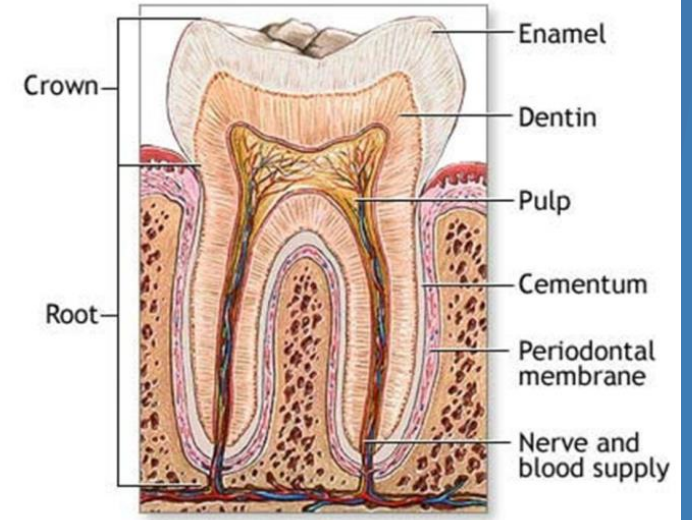
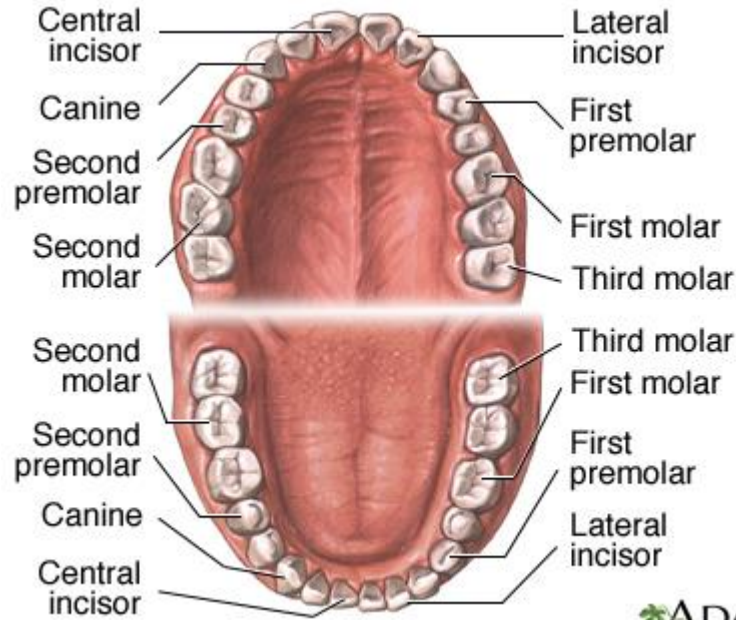
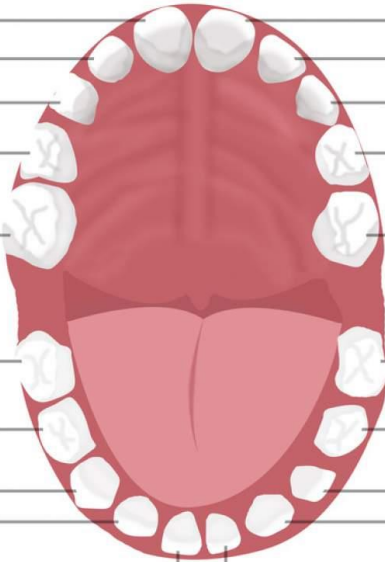
# Paediatric Quick Hits Dental Trauma

By Val Astle

# Anatomy

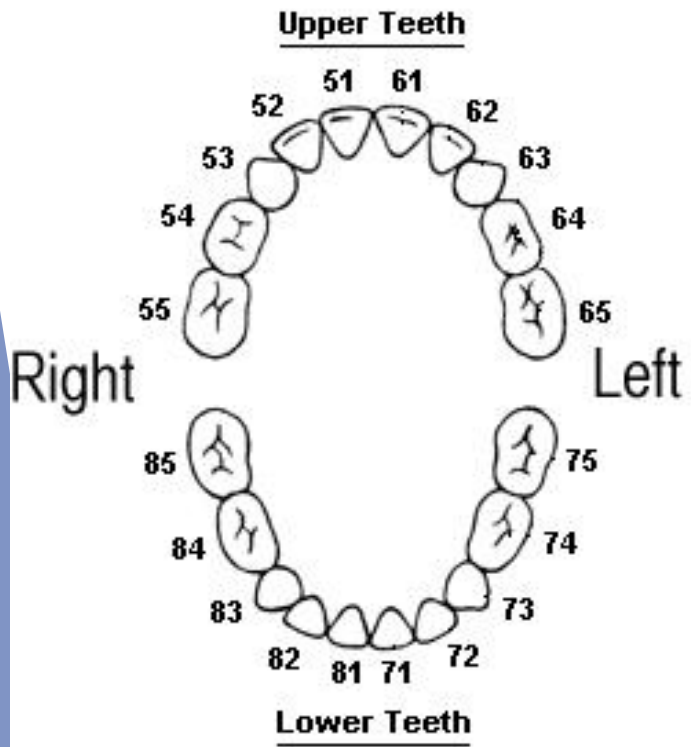
## CHILDREN TEETH ANATOMY

Age Tooth Comes In (months)	Age Tooth Is Lost (years)
Central incisor (8 - 12)	Central incisor (6 - 7)
Lateral incisor (9 - 13)	Lateral incisor (7 - 8)
Canine/cuspid (16 - 22)	Canine/cuspid (10 - 12)
First molar (13 - 19)	First molar (9 - 11)
Second molar (25 - 33)	Second molar (10 - 12)
Second molar (23 - 31)	Second molar (10 - 12)
First molar (14 - 18)	First molar (9 - 11)
Canine/cuspid (17 - 23)	Canine/cuspid (9 - 12)
Lateral incisor (10 - 16)	Lateral incisor (7 - 8)
Central incisor (6 - 10)	Central incisor (6 - 7)

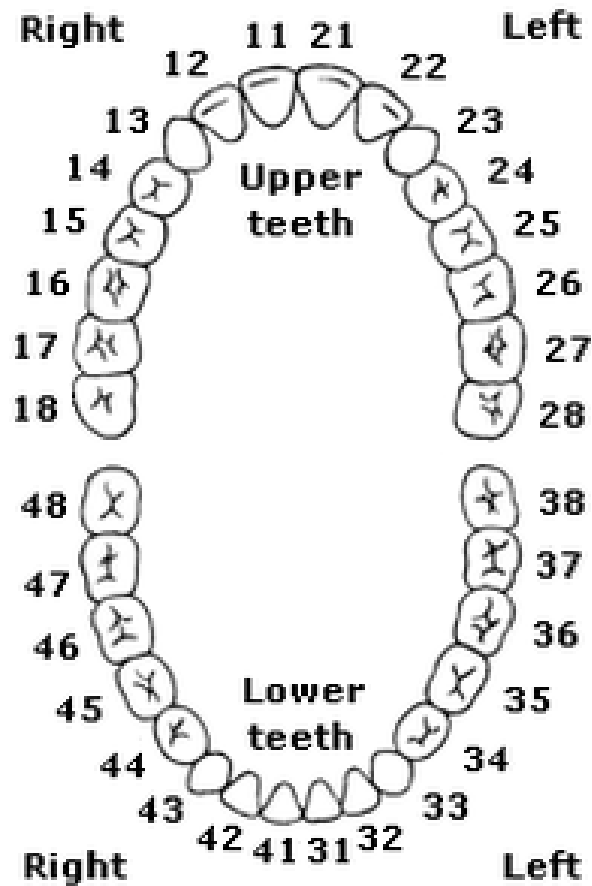


# Tooth Numbering

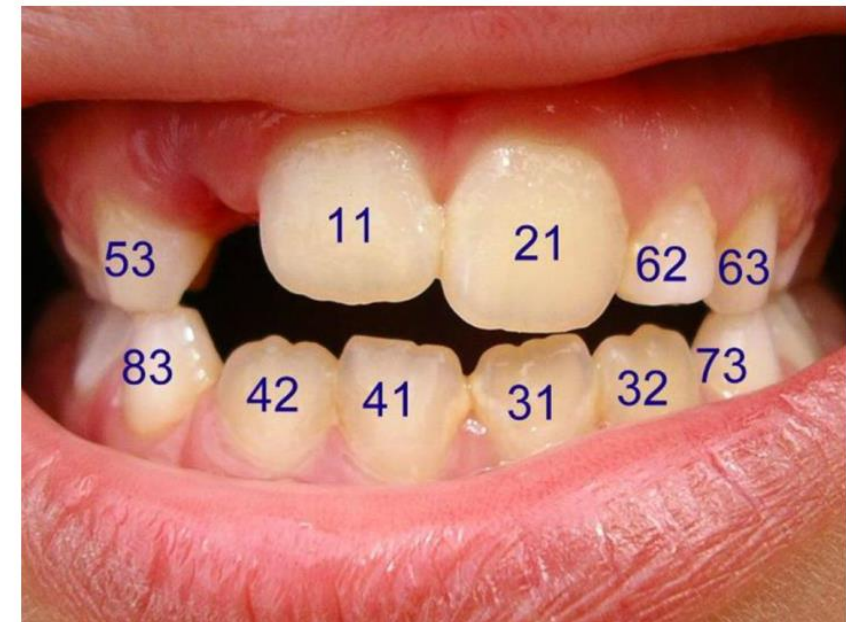## Kids Teeth Numbering



## Adult Teeth Numbering



## Mixed Dentition



# Examination and Investigations

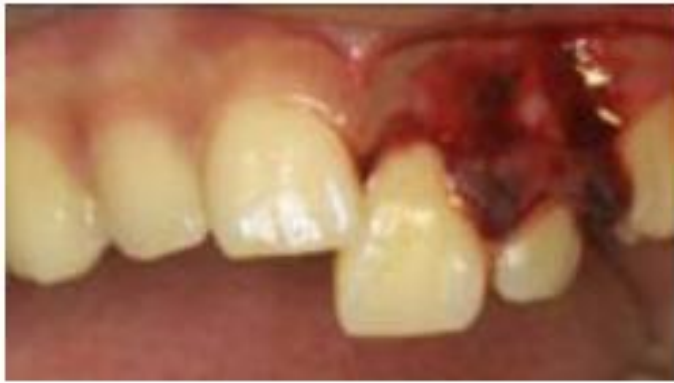## ▶ Examination

- ▶ ABCDE and C spine
  - ▶ Dental trauma often co-exists with other trauma
- ▶ Mouth- check for:
  - ▶ Symmetry
  - ▶ Bite
  - ▶ Bruising and bleeding
  - ▶ Mucosal injury
  - ▶ Bony steps
  - ▶ Type of dental injury

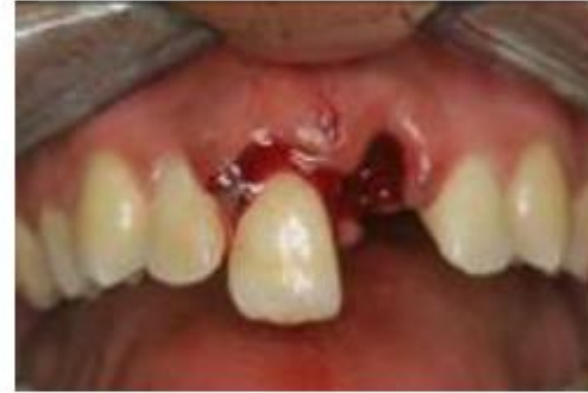## ▶ Investigations

- ▶ OPG
  - ▶ If suspect mandibular fracture or TMJ injury
- ▶ CXR
  - ▶ If ?inhaled tooth

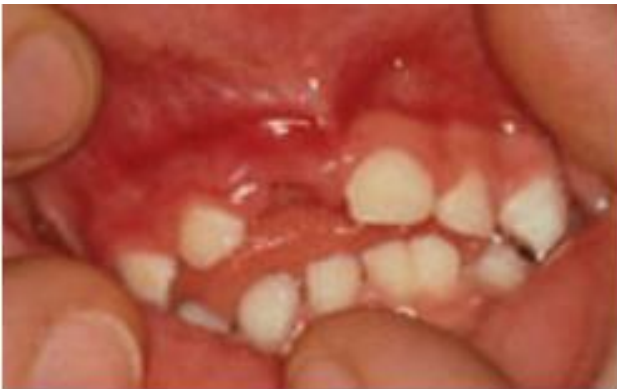# Management Loose/displaced teeth



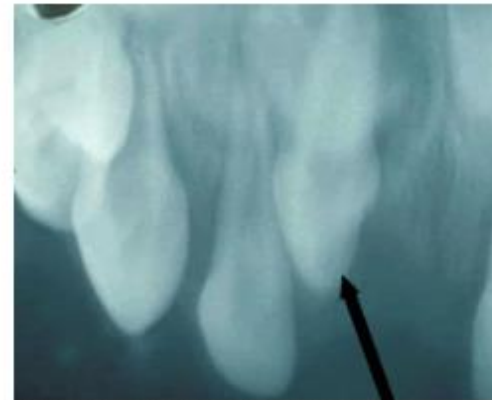
Lateral luxation and extrusive



Avulsion and lateral luxation



Intrusion

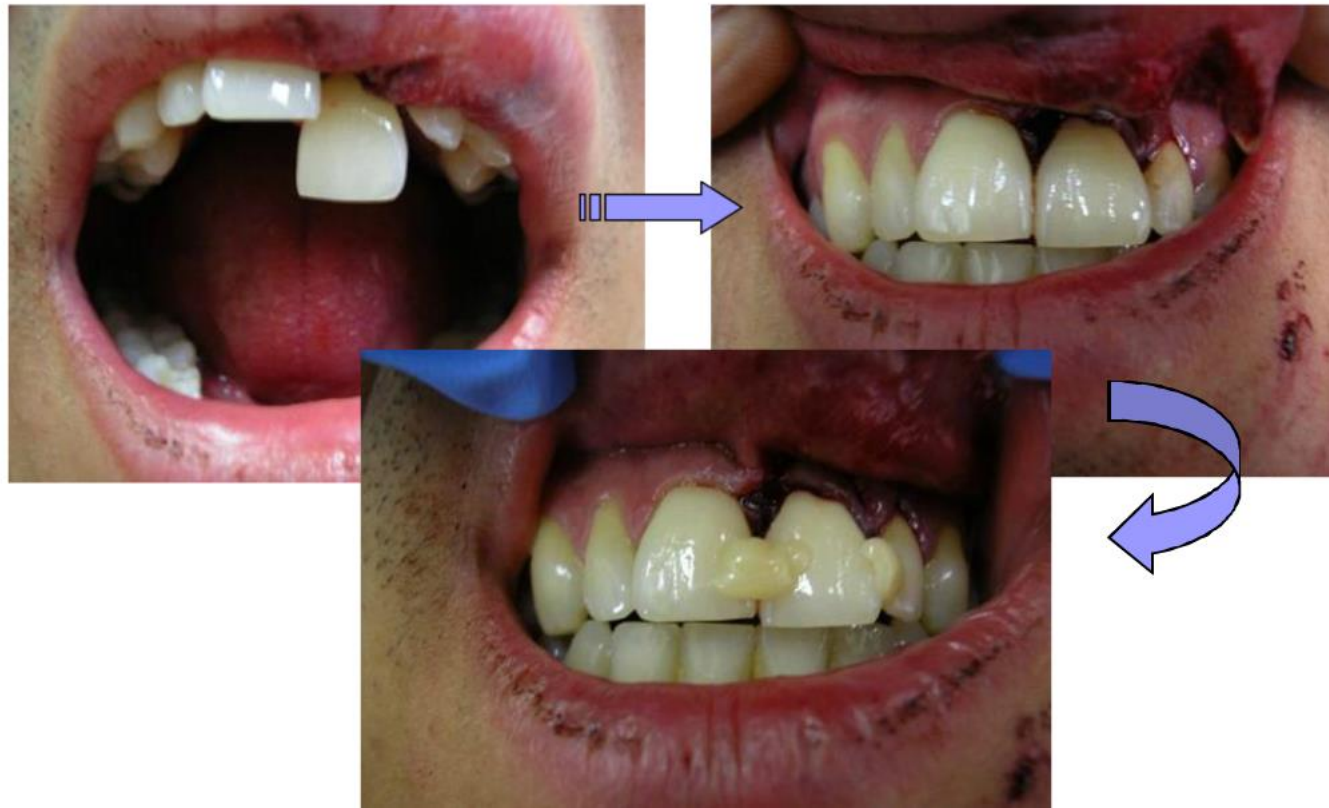

Missing primary incisor assumed avulsed. Radiograph shows it to be fully intruded.

# Management Loose/displaced teeth

Injury	Examination Findings	ED management
Concussion	Tender but firm	Review by local dentist
Subluxation	Tender and loose tooth, blood around gums	Refer to dentist
Lateral luxation	Tooth displaced anteriorly or posteriorly	Same for all 3 type of injury: Primary- monitored or extracted  Permanent- if <3mm then leave, or reposition and splint with GIC  Then refer to dentist
Extrusion	Tooth displaced, and partially out of the socket	
Intrusion	Tooth pushed into the socket	

# Management Loose/displaced teeth

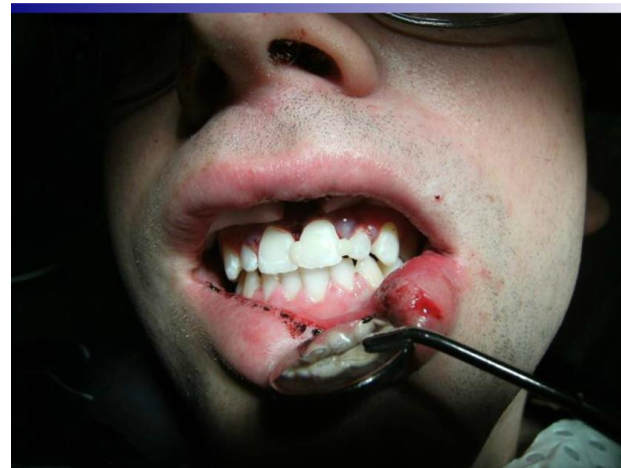
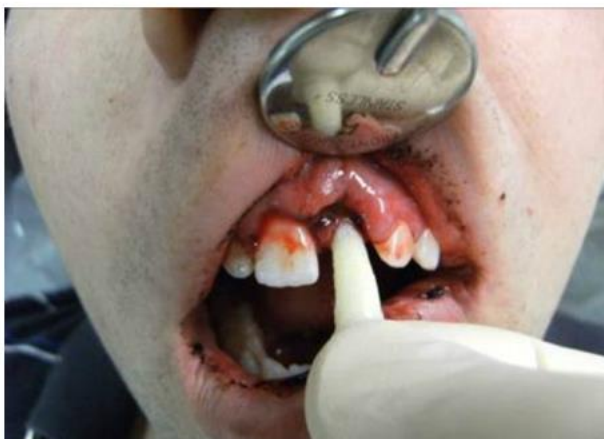
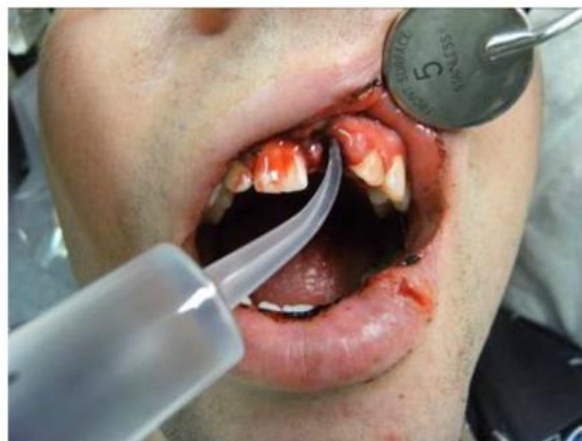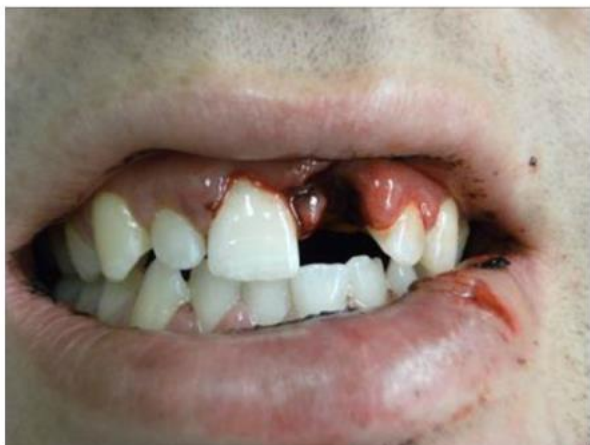# Management Loose/displaced teeth

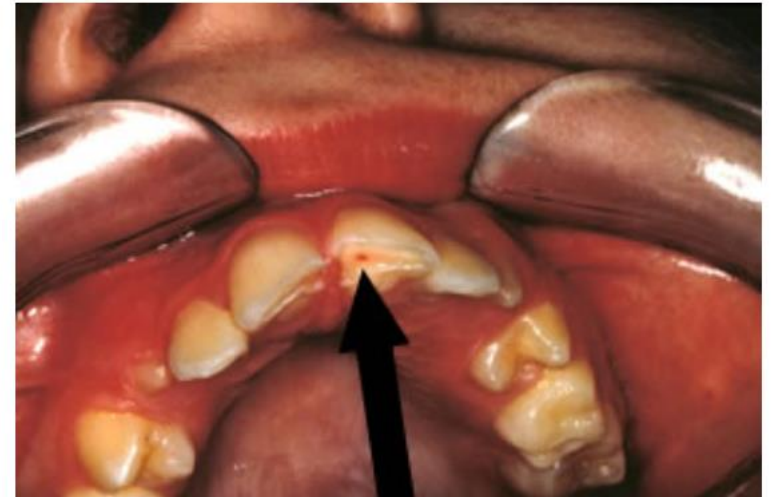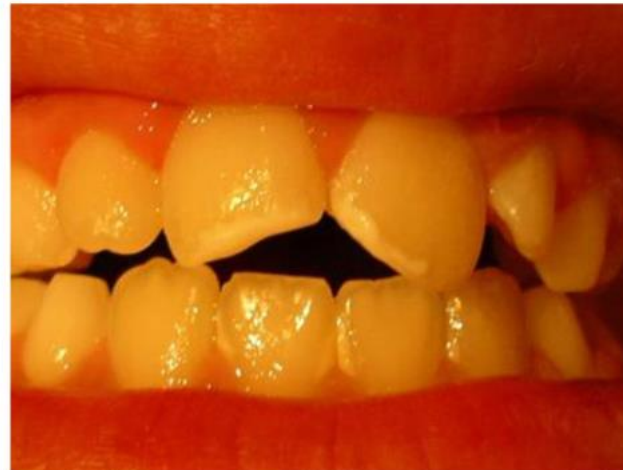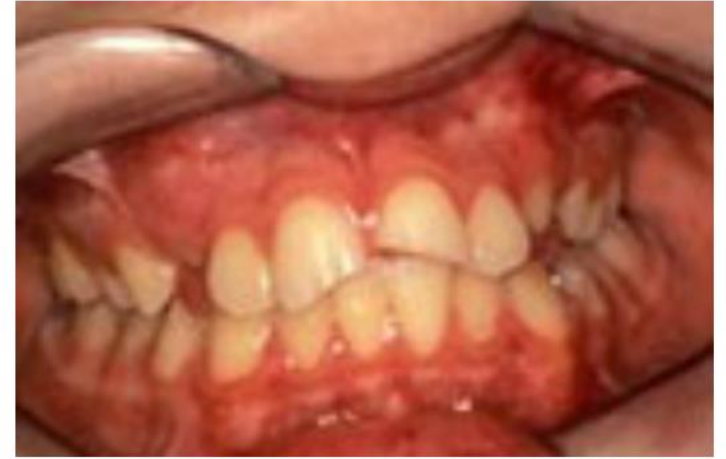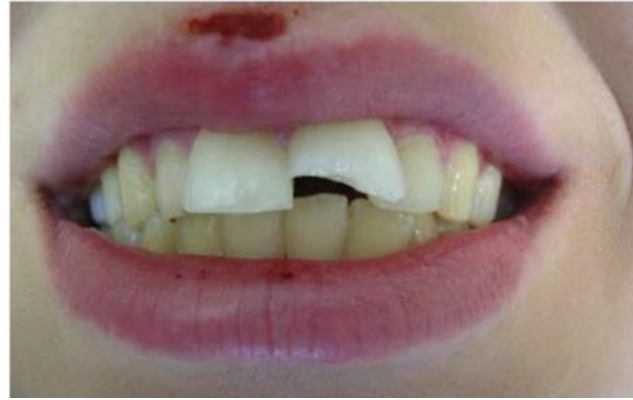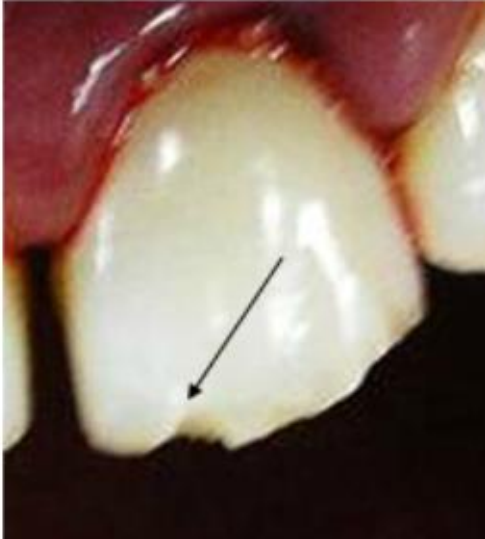Injury	Examination Findings	ED management
Avulsion	Tooth completely out of socket	<p>Primary- never reimplant</p> <p>If near avulsion and affecting bite or risk of swallowing/inhaling then extract</p> <p>Place tooth in milk while waiting Do not handle roots. Handle from the crown. For permanent teeth - put into socket</p> <ul style="list-style-type: none"><li>- Irrigate socket</li><li>- Tooth inserted convex to front,</li><li>- Bite on gauze to hold tooth temporarily in position</li><li>- Splint tooth with GIC</li></ul> <p>Refer to dentist</p>



# Management Loose/displaced teeth



# Management Fractured Teeth

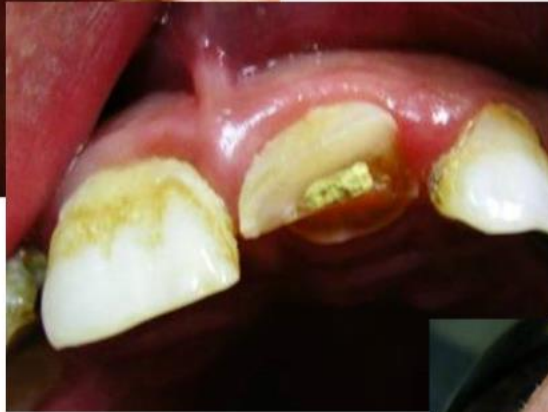
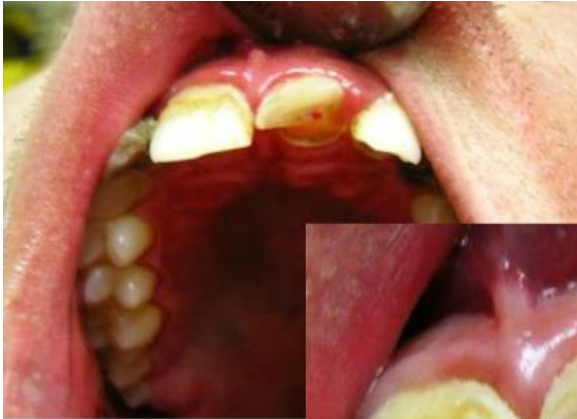
Pink pulp

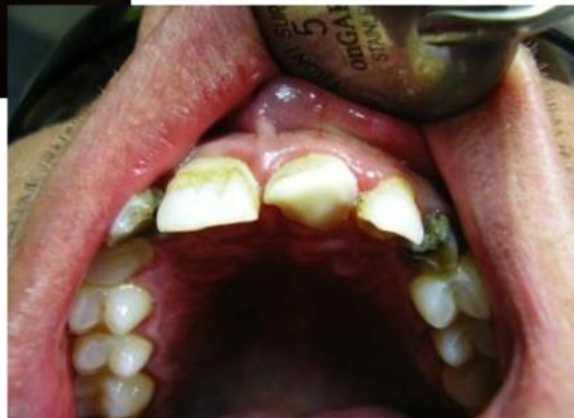# Management Fractured Teeth

INJURY	Examination findings	ED Management
Primary	Enamel only Dentine and enamel	See local dentist
Primary	Exposed pulp (pink & painful)	Call dental registrar if pulp involved because likely needs extraction
Permanent	Enamel or dentine only.	See local dentist Cover with GIC
Permanent	Exposed pulp (pink & painful, may be bleeding)	LA Wash pulp with saline and stop bleeding Cover red pulp with dycal and then once set GIC Keep any tooth fragments (in milk) for possible re-attachment

# Management Fractured Teeth




Pulp exposure  
covered with  
Dycal then  
GIC



# Where to next

- ▶ Refer to dental reg at PCH if required
- ▶ Or to community dentists- lots of options and if you ring them on behalf of the patient then often (if they can) they will squeeze the patient in sooner



**Health Facts**

## Dental services external to Perth Children's Hospital

**PCH does not provide routine dental care for children.**

The Emergency Department can offer a medical assessment for children requiring emergency treatment for dental and oral injuries, as well as relief of pain or infection. In some cases, a referral may be made to the PCH Dental Department. *Eligibility for treatment at PCH Dental Department is based on medical risk and is not automatic.*

The following services may assist with your child's routine dental care or current dental problem.

Paediatric Dental Practice	Phone	Clinician	Address
Bicton Paediatric Dentistry	9339 8200	Peter Readman	• 353 Canning Highway, Bicton. 6157
Cockburn Paediatric Dentistry	9499 4222	Vanessa William Sheyda Khadembaschi Joy Huang Jane Ho	• 6A/11 Wentworth Parade, Success. 6164
Castlegate Family Dental Care	9309 5011	Jilen Patel Mark Foster	• 7/3 Castlegate Way, Woodvale. 6026
DB Dental	1300 483 384	Vaishnavi Gopalakrishnan	• 26 Safety Bay Rd, Baldivis. 6171 • 2/1 Hobsons Gate, Currambine. • 525 Stirling Hwy, Cottesloe. 6011
Prime Children's Dentistry	9322 6977	Dr Marilyn Lobo Dr Susan Wong Dr Nandika Manchander	• 3/17 Davison Terrace Joondalup • 16B 151-153 Herdsman Parade Wembley
First Smiles	9367 9277	Vaishnavi Gopalakrishnan	• 4/234 Berrigan Drive, Jandakot. 6164

iKids	9433 6082	Timothy Johnston	<ul style="list-style-type: none"> <li>• 9/40 St Quentin Ave, Claremont. 6010</li> <li>• 94 Stirling Hwy, North Fremantle. 6159</li> </ul>
Kinderdental	9384 8800	Justin Wong Rebecca Williams Anna Buckeridge	<ul style="list-style-type: none"> <li>• 263 Stirling Hwy, Claremont. 6010</li> </ul>
Paediatric Dental Specialists	6184 7144	John Camacho Robert Anthonappa	<ul style="list-style-type: none"> <li>• Suite 2/38 Meadowvale Avenue, South Perth 6151</li> <li>• 148 Fairfield St, Mt Hawthorn. 6016</li> <li>• U3/57 Burroughs Rd, Karrinyup. 6018</li> </ul>
Toothbuds Paediatric Dentistry	6155 9899	Rodney Jennings	<ul style="list-style-type: none"> <li>• 43 Wellington Rd, Morley. 6062</li> <li>• 8 The Avenue, Midland. 6056</li> <li>• 114 Clarke St, Bunbury. 6230</li> </ul>

- **Many private general dentists** are happy to treat children. Your dentist may provide a written referral for specialist dental treatment at PCH Dental Department if required.
  - The Australian Dental Association can help you to find a dentist by suburb [Find a Dentist \(ada.org.au\)](http://www.ada.org.au)
  - The Australian and New Zealand Society of Paediatric Dentistry, a professional organisation supporting dental care for children has a find a member function <https://www.anzspd.org.au/>
- **School Dental Service** (08) 9313 0555 - Free dental care of children from pre-primary until 16 years of age, including emergency service in school holidays, Mon-Fri. Phone first for nearest centre and eligibility.
- **Oral Health Centre of WA** (08) 6457 4400 Subsidised dental care subject to means testing.
- **Community Dental Clinics** (08) 9313 0555 in-hours public dental clinics offer subsidised dental care to dependent children of Health Care Card or Pension card holders. Phone first for nearest centre and eligibility.
- **Derbari Yerrigan** (08) 1300 420 272 provides a free dental service to Aboriginal and Torres Strait Islander people. The dental clinic at DYHSAC East Perth clinic strives to provide high quality dental treatment for Derbari Yerrigan clients aged 13 and above, in a safe and culturally appropriate environment.

Government of Western Australia  
Child and Adolescent Health Service

Child and Adolescent Health Service  
15 Hospital Avenue, Nedlands, WA, 6009.  
Telephone: (08) 9436 2222  
Produced by: Dental Department  
Ref: 1620 © CAHS 2023

This document can be made available in alternative formats on request for a person with a disability.

Disclaimer: This publication is for general education and information purposes. Contact a qualified healthcare professional for any medical advice needed.  
© State of Western Australia, Child and Adolescent Health Service.

Dental services sheet available on PCH ED guideline page under 'dental trauma'